

Current Concepts in the Postoperative Care of the Rhinoplasty Patient

C. Spencer Cochran, MD, Yadranko Ducic, MD, FRCS(C), FACS, and Robert J. DeFatta, MD, PhD

Abstract: This is a systematic review of the available literature and our own personal experience regarding the optimal management of the rhinoplasty patient. The routine utilization of nasal splinting, casting and perioperative antibiotics is supported. The management of a number of common early complications is also discussed. Meticulous technique based on sound structural principles and coupled with preoperative planning and attention to wound care will result in a favorable outcome in most individuals undergoing rhinoplasty.

Key Words: rhinoplasty, complications, splinting

Meticulous attention to detail is an essential trait of the rhinoplasty surgeon. This detail-oriented approach should extend beyond the operating room to the proper evaluation and care of the rhinoplasty patient during the postoperative period. The purpose of this article is to update the reader on current concepts and trends in caring for the rhinoplasty patient during the postoperative period.

Record Keeping

The rhinoplasty surgeon's account of his operative maneuvers is an important part of the postoperative care. A detailed operative report should include the type, location, and size of the grafts utilized. It should also delineate the amount of reduction or augmentation and should include the intraoperative findings. A graphic representation of the key intraoperative maneuvers is also invaluable (Fig. 1). Whether the surgeon utilizes his own schematic representation or a commercial software program, drawings provide an effective means of depicting the operation. Together, the operative

From the University of Texas Southwestern Medical Center, Dallas, Texas; Center for Aesthetic Surgery, Colleyville, Texas, Otolaryngology and Facial Plastic Surgery Associates Fort Worth, Texas and University of Texas Southwestern Medical Center, Dallas Texas; Private Practice, Albany, New York.

Reprint requests to Yadro Ducic, MD, FRCS(C), FACS, The Center for Aesthetic Surgery, Main Street, Colleyville, TX 76034. Email: www.drducic.com

Drs. C. Spencer Cochran, Robert J. DeFatta and Yadranko Ducic have no financial disclosures to declare and no conflicts of interest.

Accepted December 4, 2007.

Copyright © 2008 by The Southern Medical Association

0038-4348/0-2000/10100-0935

report and graphic record provide critical information in the postoperative period, particularly in regards to complications and deformities, should they arise. In the event that the patient requires revision or secondary rhinoplasty, accurate records will guide the surgeon in future surgery.

Immediate Postoperative Care

Splinting and packing. Many methods of external nasal splinting following rhinoplasty have been described – aluminum, plaster, and dental compound.^{1,2} The type of splint utilized is often that of the surgeon's personal preference, but the ultimate goal is the same regardless of the technique – consistently preserve the operative results by redraping the soft tissue envelope at the conclusion of the rhinoplasty and securely bolsting the nasal framework.

The nasal dorsum should be taped from the nasion to the supratip to help control edema and protect the nasal skin from the splint in the immediate postoperative period (Fig. 2). The external nasal splint should be placed below the radix and extend to the supratip. The surgeon should avoid lateral squeezing of the splint, as this may actually lift the soft tissue envelope and create a dead space at the supratip as the splint recoils. The splint and tape should be removed at the first postoperative visit. If there continues to be significant edema, the nose can be re-taped for an additional week.

Septal splinting and intranasal packing. There has been much debate over the last several decades as to the need and optimal method of internal septal splinting. While most surgeons do not routinely pack the nose, Guyuron³ found that

Key Points

- It is necessary to redrape the nasal soft tissue envelope following rhinoplasty to avoid unfavorable outcomes.
- Splinting, casting and postoperative taping may assist in this process.
- The use of perioperative antibiotics is indicated as is nasal hygiene maintenance with saline irrigations.
- Perioperative steroids help with nausea and facial edema but have a yet undetermined, and likely minor, effect on nasal edema.

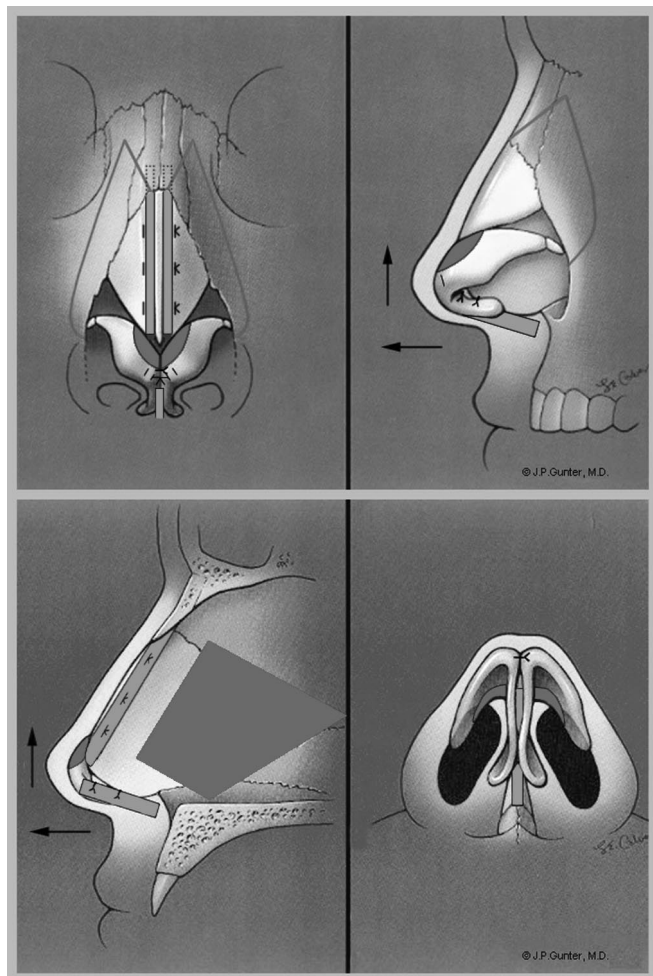


Fig. 1 Standard rhinoplasty diagram demonstrating surgical maneuvers.

patients with nasal packing were less likely to develop recurrent or residual septal deviation and synechiae compared to patients in whom no packing was used. He later demonstrated

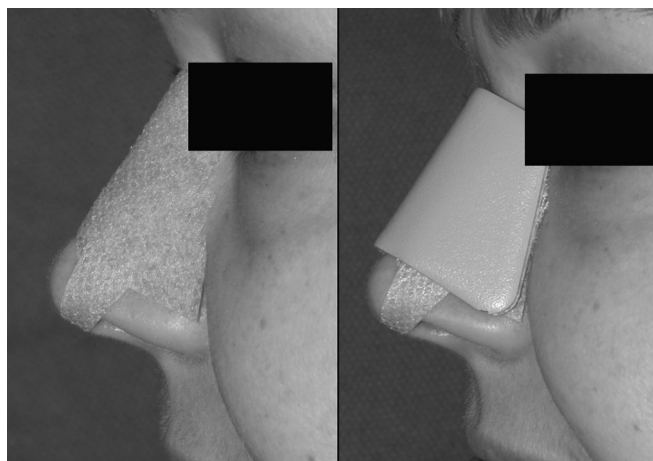


Fig. 2 External nasal dressing in position.

that septal splints provided patients with similar improvements in nasal airway obstruction as those treated with packing.⁴ Conversely, several studies have demonstrated that paired silicon splints may not prevent adhesions and can add to postoperative discomfort.^{5,6}

Nevertheless, intranasal splints are routinely used to help maintain septal stability and prevent intranasal adhesions following septorhinoplasty. The general consensus is that when placed bilaterally, these splints help stabilize the septum as the mucoperichondrium re-adheres and prevent the formation of septal hematomas.

Alternatively, a septal stitch can be placed in lieu of packing or splints. Typically, a plain gut suture is passed to and fro across the septum to reapproximate the mucoperichondrial flaps.⁷ Suturing of the flaps can aid in the prevention of septal hematoma formation by obliterating the potential dead space.⁸

The benefits of packing, splinting, and taping are not without adverse reactions or complications. Contact dermatitis has been reported in a secondary rhinoplasty patient that had nasal taping with skin tape.⁹ The treatment of contact dermatitis includes removing the offending agent and applying topical and potentially systemic steroids. A more serious complication of nasal taping is skin necrosis, which can be prevented by not taping the dorsum too tightly.

Toxic shock syndrome (TSS), an acute multisystem disease, has been described following nasal surgery with the use of both nasal packing and intranasal splints.^{10,11} TSS is usually caused by the release of an exotoxin, TSS toxin-1, created by *Staphylococcus aureus*. Symptoms occur early and include nausea, vomiting, rash, fever, and hypotension. Treatment requires immediate removal of the offending object, intensive care unit admission, and supportive care.

Postrhinoplasty nasal cysts are a rare complication of rhinoplasty. Lipogranulomas or “paraffinomas” are foreign body inclusion cysts that are thought to arise from the use of petroleum-based ointments in conjunction with nasal packing.¹² The nasal dorsum is the most common site and is thought to arise from ointment extravasation from the osteotomy sites.¹³ Lipogranulomas are treated by complete excision, usually in the setting of a secondary rhinoplasty via an open approach, to allow for adequate exposure. Meticulous closure of intranasal incisions and judicious use of nonpetroleum-based antibiotic creams should be used to help decrease the chance of lipogranuloma formation.

Medications

The rhinoplasty surgeon is often confronted with numerous therapeutic considerations when prescribing medications during the postoperative period, as well as when instructing their patients on resuming scheduled nasal medications. Thus,

the surgeon should be well versed in the available pharmacologic armamentarium and the impact of these medications on patient care.

Steroids. Corticosteroids are potent anti-inflammatory agents that are frequently administered in the perioperative period in a variety of plastic surgery procedures. There is conflicting data on the efficacy of routine systemic corticosteroid administration in rhinoplasty. Kara and Gokalan¹⁴ conducted a double-blind, randomized controlled trial with placebo control to evaluate the effects of single-dose dexamethasone use on eyelid edema, ecchymosis, and intraoperative bleeding with rhinoplasty. He determined that single-dose dexamethasone has a significant effect in decreasing upper and lower eyelid edema and upper eyelid ecchymosis for the first two days, but there was no alteration in the intraoperative blood loss or shortening of the recovery period. Similarly, several other authors also found that a single 10 mg perioperative dose of dexamethasone was beneficial in decreasing periorbital edema and ecchymosis in the early postoperative period.¹⁵

Other studies have looked at additional steroid use beyond the perioperative period. Hoffman et al¹⁶ conducted a randomized, double-blind study of intraoperative intravenous dexamethasone plus a five day postoperative course of oral prednisone following rhinoplasty. They found significantly less postoperative eyelid and paranasal edema during the first four days after surgery in those patients receiving steroids. Kargi et al¹⁷ found that three doses of 8 mg dexamethasone (administered intraoperatively and at 24 hours and 48 hours postoperatively) were more effective in decreasing facial edema and ecchymosis during the first 5 to 7 days.

While steroids may decrease early facial edema, their effects on nasal edema appear to be less efficacious. Bernstein et al¹⁸ failed to show an improvement in postoperative nasal edema using magnetic resonance imaging in patients having undergone rhinoplasty with osteotomies who received a 10 mg preoperative dose of dexamethasone. Thus, debate continues concerning the long-term benefit of routinely administering intraoperative or postoperative corticosteroids in patients undergoing rhinoplasty, as the benefits subside after the first week.

Antibiotics. Perioperative antibiotic administration is another area of debate. Randomized, controlled trials have shown that prophylactic antibiotics are effective in preventing certain surgical wound infections. In their review of over 2000 various 'clean' and 'clean-contaminated' surgical procedures, Classen et al¹⁹ found that perioperative administration of antibiotics within two hours of the surgery start time was associated with the lowest risk of surgical wound infections. Their use in nasal surgery, however, remains a point of controversy.

Topical and systemic antibiotics are frequently used in rhinoplasty. Topical antibiotic ointment has been shown to significantly decrease the growth of potentially infectious na-

sal flora and of *S aureus* in patients with nasal packing.²⁰ In a survey of plastic surgeons, Perrotti et al²¹ found that 72% of respondents used antibiotics during or after rhinoplasty, and there has been a 200% increase in the use of perioperative antibiotics in rhinoplasty between 1985 and 2000.²² Despite their widespread use and apparent efficacy, no clear guidelines exist in the literature regarding antibiotic use in aesthetic surgery. Frequently cited rationales for antibiotic prophylaxis in rhinoplasty are the fear of TSS with the use of intranasal splints, the clean-contaminated nature of the surgical wound, and the use of grafts.

Nasal saline. Topical nasal saline has been used as an adjunct in the treatment of multiple rhinologic disorders, as well as in the postoperative care of patients undergoing nasal and paranasal sinus surgery. Anecdotal evidence supports the efficacy of nasal saline. Although there is a paucity of scientific studies addressing the use of nasal saline, Tomooka et al²³ reported a statistically significant improvement in nasal symptoms in patients who used nasal saline irrigation. In support of this finding, Shone et al²⁴ demonstrated a persistent decreased mucociliary clearance three weeks following septoplasty. Thus, nasal saline may be a useful adjunct in relieving postoperative stasis of secretions, crusting, and patient discomfort.

Managing Suboptimal Results and Deformities

The pollybeak deformity. Supratip fullness, commonly referred to as a "pollybeak deformity," is a common postoperative complication of rhinoplasty in which the nasal supratip has a convex shape in relation to the nasal dorsum. The pollybeak most often results from either inadequate resection of the caudal dorsal septum and upper lateral cartilages or from over resection of these supratip structures with subsequent scar tissue formation in the resulting dead space.

Supratip taping. Taping the supratip region to recreate the supratip break and obliterate the dead space is a conservative means of treating the mild pollybeak deformity in the immediate postoperative period. Gunter advocates applying compressive tape to the supratip area (Figs. 3 and 4) nightly, until the desired supratip break created by the tape is permanent.

For the moderate-to-severe pollybeak deformity, subcutaneous injection of triamcinalone has been proven to alleviate the deformity in some patients. Hanasono et al²⁵ recommend initial subcutaneous injection of triamcinolone 1 to 2 weeks after surgery. Similarly, Guyuron et al²⁶ advocate the judicious injection of 0.2 to 0.4 cc of 20 mcg/cc of triamcinolone in the deep subcutaneous tissue if taping fails after 6 to 8 weeks. The injection is repeated at four-week intervals until the desired result is obtained.

Revision surgery. If a supratip deformity arises secondary to an inadequate dorsal resection, additional dorsal septal reduction can be accomplished in the setting of a revision surgery. Conversely, the supratip deformity caused by an

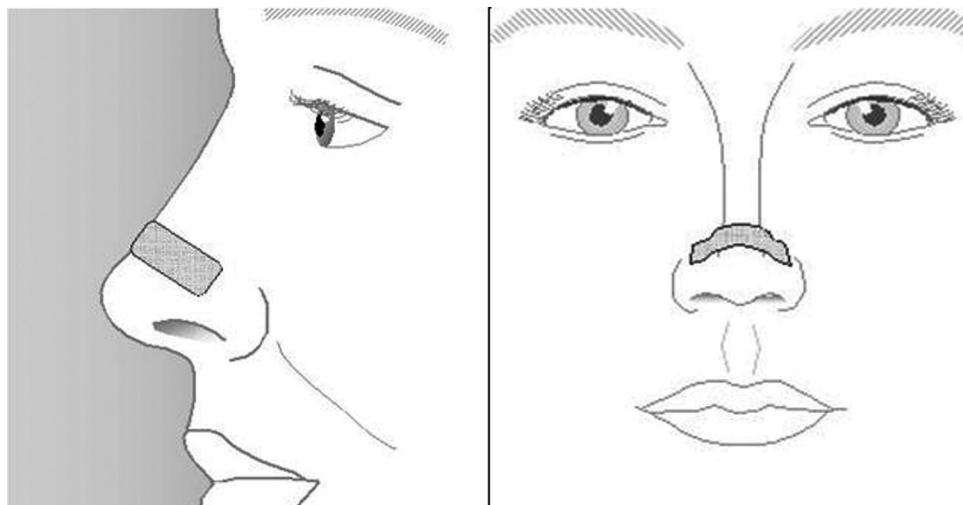


Fig. 3 Supratip taping.

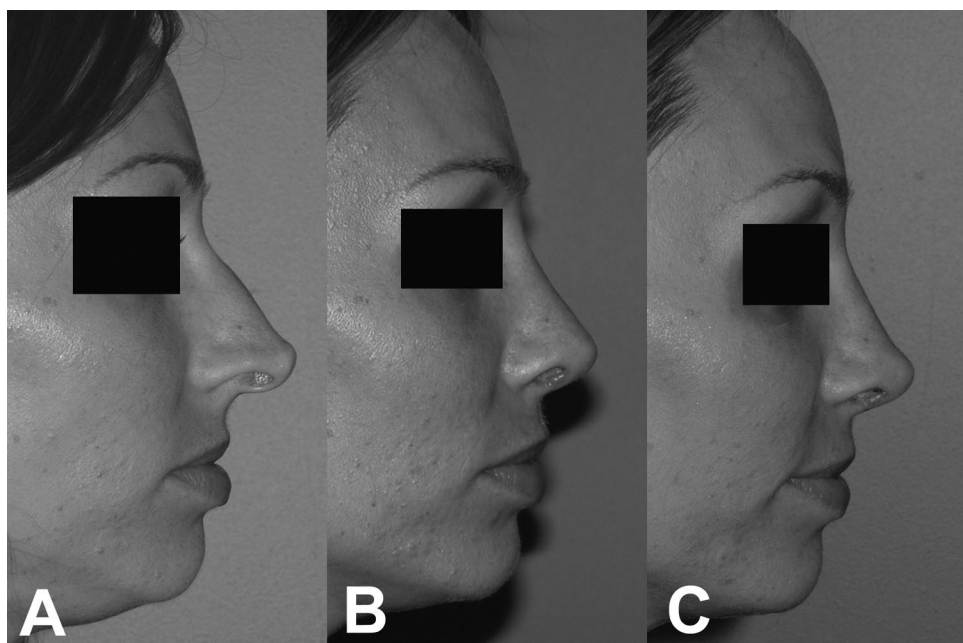
over resected dorsum may require grafting of the caudal dorsum in the setting of a revision or secondary rhinoplasty.

Deviation. Postoperative nasal deviation is a frustrating problem for both the rhinoplasty surgeon and the patient. If managed early, correction may preclude a second surgery. The nose may appear deviated secondary to shifting of the nasal bones following osteotomies, or from scar tissue contracture causing the mid-vault or tip to deviate. If recognized early in the postoperative period (one week), the nasal bones can be manipulated under local anesthetic. Conversely, the patient can be instructed on nasal massage techniques to help “train” the nose to heal in a less deviated fashion.

Localized soft tissue swelling may masquerade as a postoperative deviation, and in this case, steroid injections may alleviate a pseudodeviation.

Skin changes. Telangiectasias are small superficial vessels of the skin visible to the human eye and usually measure 0.1 to 1.0 mm in diameter.²⁷ While telangiectasias of the nose have been reported to result from rhinoplasty,^{28–30} their incidence following surgery is unknown. Rees³¹ believes that the majority of facial telangiectasias in patients who have undergone cosmetic procedures were present preoperatively and were only exacerbated by surgery. Other causes of nasal telangiectasias include significant dorsal augmentation in patients with contracted soft tissue envelopes or following alloplastic augmentation. Whether new or exacerbated, telangiectasias of the nasal skin following rhinoplasty are a frustrating problem for both the patient and the surgeon. Lasers have proven to be an effective means of treatment, but they are not without their drawbacks. The argon laser carries

Fig. 4 Effectiveness of supratip definition by simple taping. A, preoperative appearance. B, immediate postoperative appearance demonstrating a lack of an adequate supratip break and C, postoperative result at 6 months following supratip taping and demonstrating evidence of an adequate supratip break.



a risk of scarring and a relatively high risk of posttreatment pigmentary changes,³² while the pulsed dye laser (585 and 577 nm) has been shown to be a safe and highly effective means of combating telangiectasias. It has a short pulse duration (0.45 ms) that reduces the risk of severe, long-term adverse effects. However, the pulsed dye laser often leads to vessel disruption and visible purpura that may last for weeks, while the high cost and decreased availability of this laser limits its use.

Conclusion

Early postoperative evaluation serves to alert surgeons to potential complications and allows early intervention to improve suboptimal results.

References

- Ahn MS, Maas CS, Monhian N. A novel, comfortable, rapidly setting nasal splint material: results of a prospective study. *Arch Facial Plast Surg* 2003;5:189–192.
- Cunningham MW, Yousif NJ, Sanger JR, et al. Aquaplast for nasal splinting. *Ann Plast Surg* 1984;13:357–358.
- Guyuron B. Is packing after septorhinoplasty necessary? A randomized study. *Plast Reconstr Surg* 1989;84:41–44.
- Guyuron B, Vaughan C. Evaluation of stents following septoplasty. *Aesthetic Plast Surg* 1995;19:75–77.
- Cook JA, Murrant NJ, Evans KL, et al. Intranasal splints and their effects on intranasal adhesions and septal stability. *Clin Otolaryngol Allied Sci* 1992;17:24–27.
- Malki D, Quine SM, Pfliederer AG. Nasal splints, revisited. *J Laryngol Otol* 1999;113:725–727.
- Gottschalk GH. An improved septoplasty: the microsurgical suture technique. *Ann of Plast Surg* 1978;1:30–33.
- Orlandi RR, Lanza DC. Is nasal packing necessary following endoscopic sinus surgery? *Laryngoscope* 2004;114:1541–1544.
- Mabrie DC, Papel ID. An unexpected occurrence of acute contact dermatitis during rhinoplasty. *Arch Facial Plast Surg* 1999;1:320–321.
- Jacobson JA, Kasworm EM. Toxic shock syndrome after nasal surgery. Case reports and analysis of risk factors. *Arch Otolaryngol Head Neck Surg* 1986;112:329–332.
- Wagner R, Toback JM. Toxic shock syndrome following septoplasty using plastic septal splints. *Laryngoscope* 1986;96:609–610.
- Liu ES, Kridel RW. Postrhinoplasty nasal cysts and the use of petroleum-based ointments and nasal packing. *Plast Reconstr Surg* 2003;112:282–287.
- Bassichis BA, Thomas JR. Foreign-body inclusion cyst presenting on the lateral nasal sidewall 1 year after rhinoplasty. *Arch Facial Plast Surg* 2003;5:530–532.
- Kara CO, Gokalan I. Effects of single-dose steroid usage on edema, ecchymosis, and intraoperative bleeding in rhinoplasty. *Plast Reconstr Surg* 1999;104:2213–2218.
- Griffies WS, Kennedy K, Gasser C, et al. Steroids in rhinoplasty. *Laryngoscope* 1989;99:1161–1164.
- Hoffman DF, Cook TA, Quatela VC, et al. Steroids and rhinoplasty. A double-blind study. *Arch Otolaryngol Head Neck Surg* 1991;117:990–993.
- Kargi E, Hosnuter M, Babuccu O, et al. Effect of steroids on edema, ecchymosis, and intraoperative bleeding in rhinoplasty. *Ann Plastic Surg* 2003;51:570–574.
- Berinstein TH, Bane SM, Cupp CL, et al. Steroid use in rhinoplasty: an objective assessment of postoperative edema. *Ear Nose Throat J* 1998;77:40–43.
- Classen DC, Evans RS, Pestotnik SL, et al. The timing of prophylactic administration of antibiotics and the risk of surgical-wound infection. *N Eng J Med* 1992;26:281.
- Bandhauer F, Buhl D, Grossenbacher R. Antibiotic prophylaxis in rhinosurgery. *Am J Rhinol* 2002;16:135–139.
- Perrotti JA, Castor SA, Perez PC, et al. Antibiotic use in aesthetic surgery: a national survey and literature review. *Plast Reconstr Surg* 2002;109:1685–1693.
- Lyle WG, Outlaw K, Krizek TJ, et al. Prophylactic antibiotics in plastic surgery: trends of use over 25 years of an evolving specialty. *Aesthetic Surg J* 2001;23:117.
- Tomooka LT, Murphy C, Davidson TM. Clinical study and literature review of nasal irrigation. *Laryngoscope* 2000;110:1189–1193.
- Shone GR, Yardley MP, Knight LC. Mucociliary function in the early weeks after nasal surgery. *Rhinology* 1990;28:265–268.
- Hanasono MM, Kridel RW, Pastorek NJ, et al. Correction of the soft tissue pollybeak using triamcinalone injection. *Arch Facial Plast Surg* 2002;4:26–30.
- Guyuron B, DeLuca L, Lash R. Supratip deformity: a closer look. *Plast Reconstr Surg* 2000;105:1140–1151.
- Goldman MP, Bennet RG. Treatment of telangiectasia: a review. *J Am Acad Dermatol* 1987;17:167–182.
- Padovan IF, Jugo SB. The complications of external rhinoplasty. *Ear Nose Throat J* 1991;70:454–456.
- Dickens CH. Argon laser treatment of the red nose. *J Dermatol Surg Oncol* 1990;16:33–36.
- Noe JM, Finely J, Rosen S, et al. Postrhinoplasty “red nose”: differential diagnosis and treatment by laser. *Plast Reconstr Surg* 1981;67:661–664.
- Rees TD. Point and counterpoint, parts x, xi, and xii, in Rees TD, Baker DC, Tabbal N (eds): *Rhinoplasty Problems and Controversies—A Discussion With the Experts*. St. Louis, Mosby, 1998, p 368.
- Scheepers JH, Quaba AA. Clinical experience in the treatment of the “red nose” using the flashlamp-pumped pulsed dye laser. *Aesthetic Plast Surg* 1994;18:57–60.