

CASE REPORTS

Inverting papilloma of the base of tongue with malignant transformation

JESSE E. SMITH, MD, and YADRANKO DUCIC, MD, Dallas and Fort Worth, Texas

We report a rare case of invasive moderately differentiated squamous carcinoma arising within an inverted papilloma at the base of the tongue in a symptomatic man.

CASE REPORT

A 48-year-old otherwise healthy man presented to his primary care physician with complaints of persistent globus sensation, dysphagia, neck pain, and otalgia. Over the course of 2 years, the patient was referred to 3 otolaryngologists, the last of whom took the patient to the operating room for a direct laryngoscopy and biopsy. The patient was unable to be intubated in the operating room and underwent emergent tracheotomy to secure his airway.

The patient was then referred to our clinic because of suspected malignancy. In the office, an ill-defined tongue base induration was noted by palpation. Fiberoptic laryngoscopy showed a fullness of the tongue base, but there were no mucosal abnormalities. A computed tomography scan (CT) of the neck, with intravenous contrast, showed a mild asymmetry of the base of the tongue (Fig 1). The epiglottis appeared thickened, and there was a mass noted within the base of tongue, approximately at the level of the hyoid bone. The remainder of the patient's metastatic work-up, including liver function and thyroid function tests, and a CT of the chest, was normal.

The patient was taken back to the operating room for an examination under anesthesia and direct laryngoscopy with biopsy samples; this procedure confirmed both the fiberoptic examination and CT findings. Deep and directed biopsies were performed, and samples were sent for both frozen and permanent sections.

Histology

Microscopic evaluation of the specimen demonstrated squamous proliferation characterized by large sheets of well-circumscribed epithelial cells embedded within a fibrous stroma. Many of the epithelial cells demonstrated marked atypia with nuclear pleiomorphism and increased mitotic figures. The overlying squamous mucosa shows focal areas of dysplastic change. Several regions of the biopsy show a pattern characteristic of inverting papilloma (Fig 2).

Treatment and Follow-up

After careful review of the treatment options with the patient and his family, primary chemotherapy and radiation therapy were initiated, with surgery reserved as a salvage option. The patient tolerated his concomitant treatment well. One-year follow-up CT scan and biopsies showed evidence of inflammation but demonstrated no signs of malignancy. The patient is now 18 months post treatment without manifestations of recurrent disease.

DISCUSSION

Inverting schneiderian papillomas arise from a proliferation of reserve cells in the schneiderian mucosa. This ectodermally derived mucosa lines the walls of the nasal cavity and paranasal sinuses. These lesions are one of the most common benign tumors of the nose and paranasal sinuses. Patients with schneiderian inverting papillomas often present between their fifth and seventh decade with symptoms of unilateral nasal airway obstruction; however, sinusitis, epistaxis, and rhinorrhea

From the Department of Otolaryngology–Head and Neck Surgery, University of Texas Southwestern Medical Center at Dallas, and Division of Otolaryngology and Facial Plastic Surgery, John Peter Smith Hospital.

Reprint requests: Y. Ducic, MD, Director, Otolaryngology and Facial Plastic Surgery, John Peter Smith Hospital, 1500 South Main St, Fort Worth, TX 76104; e-mail, yducic@aol.com.

Otolaryngol Head Neck Surg 2004;130:142-4.

0194-5998/\$30.00

Copyright © 2004 by the American Academy of Otolaryngology–Head and Neck Surgery Foundation, Inc.

doi:10.1016/S0194-5998(03)01450-5

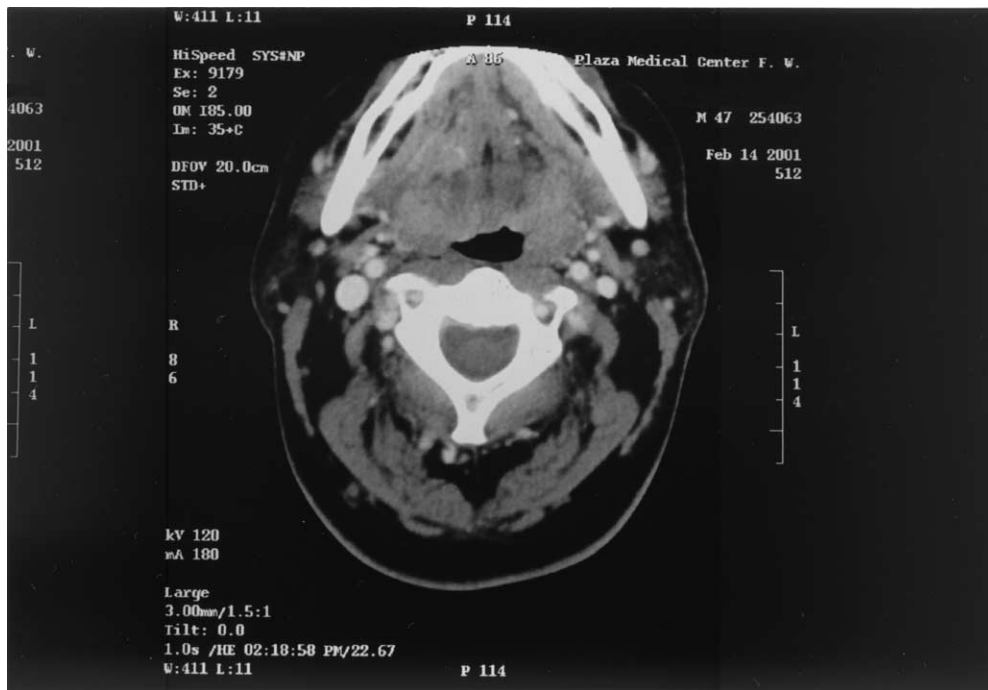


Fig 1. Axial CT scan of neck demonstrating fullness in the right base of tongue area.

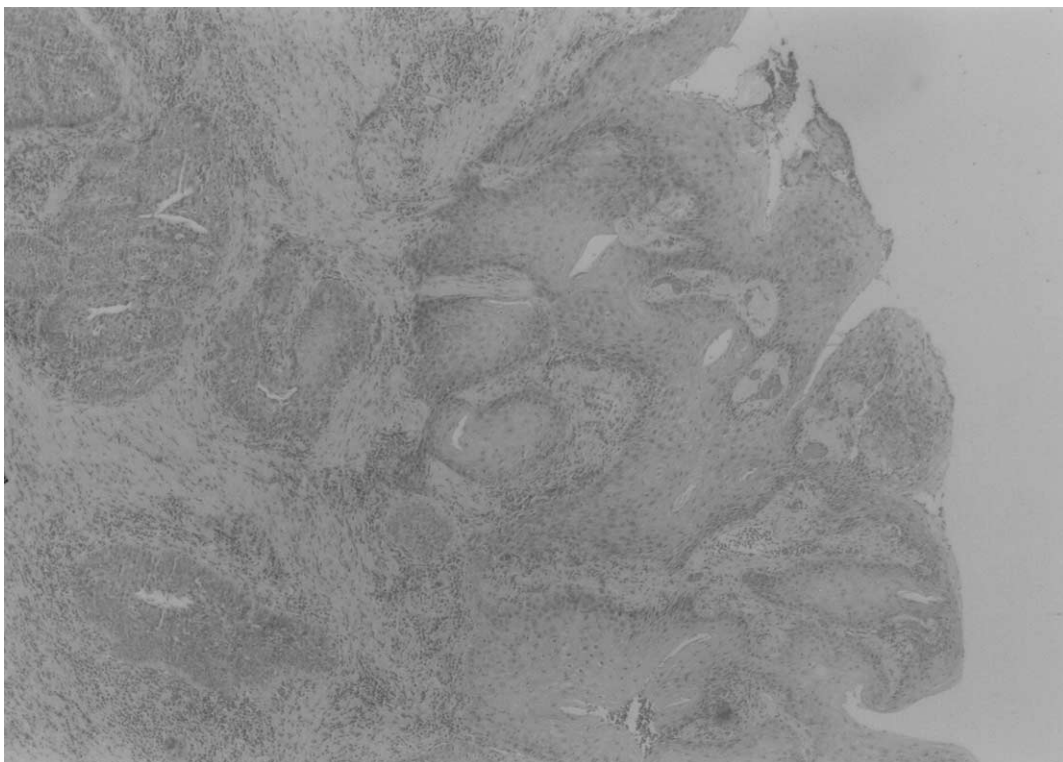


Fig 2. Hematoxylin and eosin photomicrograph ($\times 50$ magnification) demonstrating nests of invasive squamous cell carcinoma within a classic inverting papilloma.

are common as well.¹ Nasal and paranasal inverting papillomas are notorious for their pernicious nature, destructive capacity, tendency to recur, and their potential for malignant transformation. Males are affected approximately 4 times as frequently as females.² Although the etiology of inverting schneiderian papillomas is unconfirmed, a number of recent articles suggest that viral infection may play an important role. Malignant change has been reported in 5% to 27% of inverting papillomas.^{2,3} Inverting schneiderian papillomas are occasionally referred to as epithelial papilloma of the sinonasal tract, squamous papillary epithelioma, polyp with inverting metaplasia, soft papilloma, papillary fibroma, and transitional cell papilloma. Regardless of the exact name, these lesions represent benign, locally aggressive tumors that commonly originate from the lateral nasal wall in the region of the middle meatus. Other less common sites of involvement include orbital structures, the frontal sinus, the sphenoid sinus, the nasal septum, the oropharynx, the nasopharynx, the cervical lymph nodes, and the hypopharynx.⁴ To our knowledge, no other cases of squamous cell carcinoma developing within an inverting papilloma of the tongue base have been reported. An unusual characteristic is the submucosal characteristic of this lesion, derived from areas primarily of endodermal origin. Nosanchuk⁵ reported a symptomatic case of posterior oropharyngeal inverted papilloma, which was excised. Sulica et al⁴ reported on inverting papillomas of the nasopharynx

and oropharynx; however, most of these were noted in the posterior oropharynx as well, and all patients were asymptomatic. Of the 16 cases reported of nonnasal and nonparanasal inverting papillomas, only a single patient with nasopharyngeal inverting papilloma had squamous cell carcinoma arising from the aberrant rest of cells.

CONCLUSION

A rare case of invasive moderately differentiated squamous carcinoma arising within an inverted papilloma at the base of the tongue in a symptomatic male was described. Deep biopsy samples in this area were needed for a definitive diagnosis, which was made 2 years after the patient's symptoms began. This substantiates the ability of inverting schneiderian papillomas to be located beyond the boundaries of the nose and paranasal sinuses. Its submucosal nature in this particular patient and its slow, indolent progression may make this a difficult diagnosis.

REFERENCES

1. Myers EN, Fernau JL, Johnson JT, et al. Management of inverted papilloma. *Laryngoscope* 1990;100:481-90.
2. Lawson W, Ho BT, Shaari CM, et al. Inverted papilloma: a report of 112 cases. *Laryngoscope* 1995;105:282-8.
3. Lesperance MM, Esclamado RM. Squamous cell carcinoma arising in inverted papilloma. *Laryngoscope* 1995; 105:178-83.
4. Sulica RL, Debo RF, Wenig BM, et al. Schneiderian papillomas of the pharynx. *Ann Otol Rhinol Laryngol* 1999;108:392-7.
5. Nosanchuk JS. Oropharyngeal inverted papilloma. *Arch Otolaryngol* 1974;100:71-2.