

Locoregional and Microvascular Free Tissue Reconstruction of the Lateral Skull Base

Demetri Arnaoutakis, MD¹ Sameep Kadakia, MD¹ Manoj Abraham, MD² Thomas Lee, MD³
Yadranko Ducic, MD¹

¹Otolaryngology and Facial Plastic Surgery Associates, Fort Worth, Texas

²Department of Otolaryngology-Head and Neck Surgery, New York Medical College, Valhalla, New York

³Department of Otolaryngology-Head and Neck Surgery, Virginia Commonwealth University, Richmond, Virginia

Address for correspondence Yadranko Ducic, MD, Otolaryngology and Facial Plastic Surgery Associates, 923 Pennsylvania Avenue, Suite 100, Fort Worth, TX 76104 (e-mail: Yducic@sbcglobal.net).

Semin Plast Surg 2017;31:197–202.

Abstract

Keywords

- ▶ lateral skull base defects
- ▶ local flaps
- ▶ pedicled flaps
- ▶ microvascular free tissue transfer
- ▶ head and neck reconstruction

The goals of reconstruction following any oncologic extirpation are preservation of function, restoration of cosmesis, and avoidance of morbidity. Anatomically, the lateral skull base is complex and conceptually intricate due to its three-dimensional morphology. The temporal bone articulates with five other cranial bones and forms many sutures and foramina through which pass critical neural and vascular structures. Remnant defects following resection of lateral skull base tumors are often not amenable to primary closure. As such, numerous techniques have been described for reconstruction including local rotational muscle flaps, pedicled flaps with skin paddle, or free tissue transfer. In this review, the advantages and disadvantages of each reconstructive method will be discussed as well as their potential complications.

Lateral temporal bone defects most commonly occur following resection of malignant tumors. However, they can also arise secondary to chronic infection, trauma, and osteoradionecrosis. The temporal bone rests in the central position of the lateral skull base and serves as the main landmark in lateral skull base anatomy.

Lateral skull base resections range from subtotal or total parotidectomy with external auditory canal sleeve resection to subtotal lateral temporal bone resection to even more comprehensive total temporal bone resection with petrosectomy.

The involvement of lateral temporal bone structures by either primary parotid tumors or secondary involvement via metastatic disease to intraparotid lymph nodes is not uncommon. As these masses enlarge, they will consume adjacent structures. The extent of tumor burden and involved structures that require excision will not only dictate the volume of the defect, but also the amount of composite tissue needed for reconstruction. The tissues eventually resected will determine what adjacent structures are exposed and dictate certain steps within the reconstructive paradigm.

In general, the principal goals of skull base reconstruction are to create a safe wound by separating the intracranial and extracranial spaces, to maintain function by covering vital structures, and to restore cosmesis. Numerous techniques have been described to achieve these goals including local flaps, pedicled flaps, and microvascular free tissue transfer.¹ Vascularized muscle proves superior in its ability to seal skull base defects and act as a “plug” to prevent cerebrospinal fluid (CSF) leaks. Closing off dead space will help prevent fluid accumulation such as seroma or hematoma. Finally, adjuvant therapy is often required following resection, and as such, the reconstructed tissue should be able to withstand further treatment if necessary.²

Preoperative Planning

There are specific objectives to the general goals outlined in the introduction section that must be fulfilled to achieve successful skull base reconstruction: (1) replacement of lost skin coverage, (2) watertight repair of dural defects, (3)

intermediate placement of vascularized tissue between exposed durus and adjacent spaces, (4) provision of stable skeletal support where areas of craniofacial skeleton have been removed, (5) obliteration of dead space, and (6) rehabilitation of cranial nerve injuries. Proper selection of an effective reconstructive technique will maximize the chances in attaining these objectives while minimizing the risks of complications. Thorough analysis of imaging studies, computed tomography (CT), or magnetic resonance imaging (MRI) will assist in planning for the reconstruction.

Cerebrospinal fluid fistulas, dural defects, or exposure of critical neurovascular structures will complicate reconstruction if present. Persistent CSF leaks increase the risk for meningitis, which can occur in 8 to 41% of cases.³ As such, every effort to repair dural injuries through direct closure with running locking sutures or patching must be made. Pericranium and temporalis fascia are the two most common autografts used for dural patching as they are readily available.⁴ Fibrin glue serves as a valuable adjunct to watertight dural closure as it can help bond onlay grafts to the underlying dural layer. Vascularized tissue interposed between the intracranial compartment and adjacent spaces will further prevent necrosis, wound contamination, infection, or CSF leak.

Reconstruction of bony skull base defects remains a controversial topic. There is limited discussion specific to the lateral skull base. However, some have advocated for routine repair of large anterior bony defects using a three-layer closure with mesh, calvarial bone grafts, and pericranial flaps.⁵ Others believe indications for osseous repair include (1) only large enough defects where gross brain herniation occurs, (2) maxillary or mandibular/glenoid fossa defects that result in facial deformity, (3) orbital roof defects resulting in pulsatile exophthalmos from herniating brain pressure, or (4) cranio-orbital defects that result in inadequate soft tissue support and deformity.¹ When an isolated bony defect occurs, it may be easiest to use alloplastic materials such as titanium mesh that are then completely covered with vascularized soft tissue. Otherwise, split-thickness calvarial grafts provide a useful readily available bone source. If extensive defects of the lateral skull base require bony repair as well as soft tissue bulk, then these defects are best reconstructed with osseous composite free tissue transfer such as the scapula, fibula osteocutaneous, or radial forearm flaps.

Key patient factors must also be considered, including underlying medical comorbid conditions such as diabetes mellitus and peripheral vascular disease. Intraoperatively, the defect size must be determined as well as remnant normal that can aid in closure. Another important aspect to consider is what additional treatments may be necessary. Postoperative radiation therapy is often required after oncologic resection of malignant skull base tumors. The reconstructive surgeon must anticipate potential wound challenges from radiation, such as timing, dose, and field of treatment. Vascularized tissue will help avoid complications of radiation therapy compared with other sources of tissue.

A classification scheme was created to categorize lateral temporal bone defects: Class I, preauricular defects with external auditory canal preservation; Class II, lateral temporal

bone resection with auricle preservation; Class III, lateral temporal bone resection with total auriclectomy.⁶ The authors concluded that larger class defects are best reconstructed with free flaps. In a similar line of thought, Patel et al performed a large retrospective review to analyze key factors that influence the management of lateral skull base defects.⁷ They developed an algorithm that provides a simple yet comprehensive approach to selecting an option that takes key perioperative factors into consideration.

Local Regional Reconstruction

Temporalis Muscle Rotational Flap

The temporalis muscle flap is a popular choice for reconstruction of smaller defects given its proximity. It is an axial flap based on the anterior and posterior deep temporal arteries. Hanasono et al reported their experience with it, using muscle only in 10 patients and a skin graft over the muscle in an additional 17 patients.⁸ In their series, there were no episodes of dehiscence, hematoma, or seroma. Harvest time was significantly less when compared with free tissue transfer. Although overall this flap offers minimal donor site morbidity, it does leave a temporal concavity when the entire muscle is used. Various measures are available to counteract temporal hollowing such as preservation of the temporal fat pad and zygoma reconstruction.⁹ There is no cutaneous portion to the flap so skin grafting may be required when a cutaneous defect is present. If the resection extends to the infratemporal fossa, the temporalis muscle vascular supply may have been compromised during the ablative portion of the surgery.

The flap is harvested by dissecting the temporalis muscle from the temporal fossa. The insertion to the zygoma should be transected to enhance mobilization. To protect the frontal branches of the facial nerve, the superficial layer of the deep temporal fascia is incised along a line that extends from the superior orbital rim to the root of the zygoma. The plane of dissection then enters deep to this fascial layer. The arc of rotation may be lengthened by dividing the insertion of the temporalis muscle to the coronoid process of the mandible.

Trapezius Flap

Regional flap reconstruction must be considered when a larger volume of tissue is needed or when seeking tissue outside of a local radiated field. Panje was the first to utilize the myocutaneous trapezius flap for lateral temporal bone defect coverage.¹⁰ With the patient in the lateral decubitus position, the upper portion of the trapezius muscle overlying the deltoid muscle can be harvested. It has a reliable vascular pedicle from the transverse cervical artery. Marzo et al used this technique on eight patients without any immediate wound complications.¹¹ Partial trapezius flap loss did occur in one patient with a history of prior radiation to the auricle. All donor sites were closed primarily.

Although this flap is a local rotational flap that can be harvested through the surgical defect, skin graft coverage is necessary. Other drawbacks of this flap include the limited arc of rotation, narrow width size, and shoulder dysfunction.

If a larger flap with more muscle mass is required, the risk of donor site complications can be high and marginal flap circulation may be compromised.¹² Yet, this flap can still provide more volume and the increased arc of rotation compared with the temporalis flap.

Supraclavicular Flap

Over the last decade, the supraclavicular flap has garnered increased popularity for head and neck reconstruction. This rise in popularity occurred following modifications that were made in flap harvest to negate its originally high incidence of distal tip necrosis.^{13,14} Now, it can offer a broad surface area of fasciocutaneous tissue with sufficient arc of rotation to reach the lateral skull base. It is based off the supraclavicular vessels from the thyrocervical trunk and can provide skin with compatible color and texture to the recipient site. The flap is demarcated by the posterior border of the sternocleidomastoid, the clavicle, and the external jugular vein. **Fig. 1** shows the harvest of a supraclavicular flap. When compared with free flap reconstruction, utilization of this flap significantly decreases operative time.¹⁵

In the largest case series to date, Emerick et al described their experience with 16 patients using the supraclavicular artery island flap (SCAIF) for parotid or lateral skull base defects.¹⁶ No complete flap loss occurred, and only one partial flap loss was reported that did require operative debridement, but no further reconstructive procedures after local wound care. The average flap size was 7 × 10 cm. The authors conclude the advantages to this flap include (1) simplicity in harvest, (2) limited donor site defect, and (3) excellent skin match with regards to color and texture. Finally, the flap may be tunneled under the skin which reduces unsightly incisions and improves aesthetic outcomes.

Defects larger than 10 to 15 cm in width may extend beyond the angiosome of the SCAIF and challenge the surgeon’s ability to achieve primary closure at the donor site. In such situations, free tissue transfer may be a better option. Patients with minimal subcutaneous tissue over the ventral deltoid may also prove suboptimal for reconstruction of a comprehensive temporal bone defect. Muscle offered from a bulkier flap may then be a better option. If cervical lymphadenectomy must be performed for oncologic reasons, the SCAIF will not be an option because the blood supply will be disrupted.

Pectoralis Major Pedicle Flap

The pectoralis major myocutaneous flap remains the most frequently used flap in head and neck reconstruction given its reliability and relative ease of harvest. It is based superiorly off the pectoral branch of the thoracoacromial artery and is raised with a skin paddle from the inferior aspect of the muscle. **Fig. 2** shows the anatomy of the pectoralis flap. Yet, its application in the reconstruction of the lateral skull base was initially restricted to defects inferior to the external auditory canal because of the perceived difficulty in achieving sufficient flap length to ensure tension-free watertight closure.¹⁷ Surgeons raised concerns over its possible excess bulk limiting to reach to the lateral skull base resulting in wound dehiscence, propensity for venous congestion when flap reach is maximized, and reach of the skin paddle.

In a series of eight patients using the pectoralis flap, Resto et al reported no cases of dehiscence or wound infection.¹⁸ They believe this was possible through five modifications in their flap harvest which enhanced reach with reliable viability: (1) the skin paddle is designed over the entire length of the muscle, (2) a 5-cm cuff of the superior rectus sheath is harvested in continuity with the distal pectoralis major muscle, (3) motor nerves around the proximal pedicle are

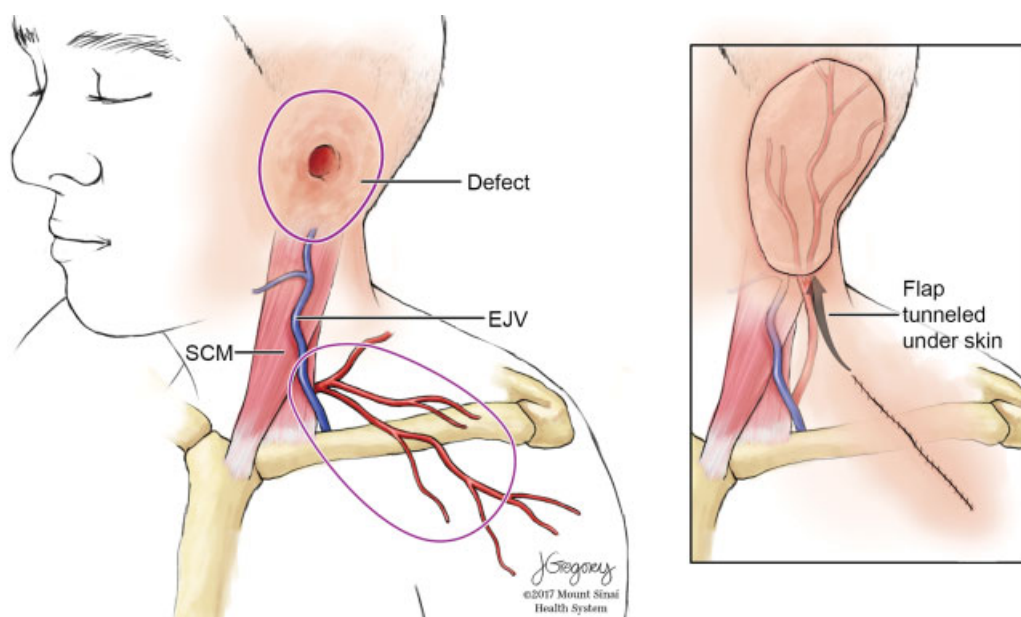


Fig. 1 Anatomy of the supraclavicular flap along with an inset showing reconstruction of a defect with the supraclavicular flap (Artwork courtesy of Jill K. Gregory from the Mount Sinai Health System). EJV, external jugular vein; SCM, sternocleidomastoid muscle.

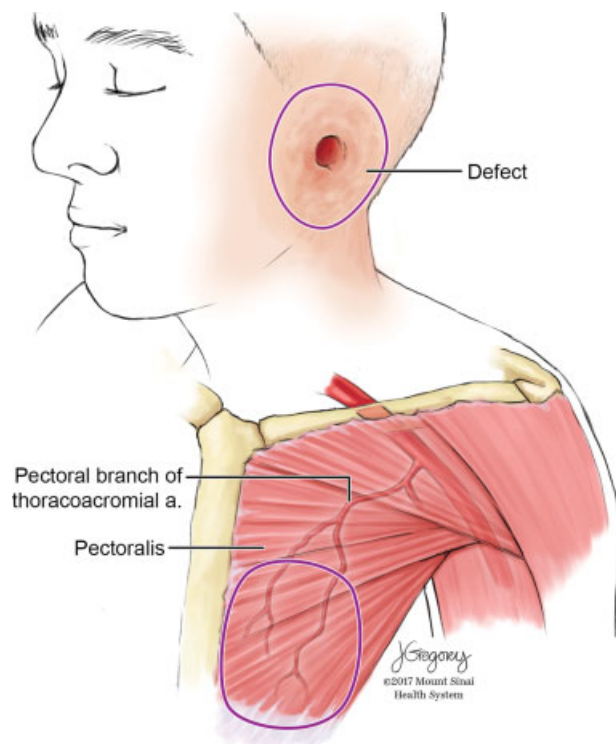


Fig. 2 Anatomy of the pectoralis major flap (Artwork courtesy of Jill K. Gregory from the Mount Sinai Health System).

identified and severed, (4) the flap is suspended by the harvested rectus sheath, and (5) the flap skin paddle inset is incorporated into the neck incision. One patient did develop a chest wall hematoma requiring operative drainage. Overall, the flap can provide large volume reconstruction with adequate muscle coverage for dead space and skin to cover superficial wounds.

Submental Island Flap

Originally described by Martin et al, the submental flap is a versatile, reliable flap that can be harvested to provide a generous quantity of muscle, including bilateral mylohyoid and anterior belly of digastric muscles.¹⁹ It is based off a unilateral submental pedicle and can be harvested with a small or large cutaneous paddle. Due to its muscular component, favorable arc of rotation, and location within the surgical field, it can be a desirable option for reconstruction with low donor site morbidity.²⁰

A case series from the Mayo Clinic involved 31 patients with lateral temporal bone defects, of which 16 were reconstructed using the submental flap.²¹ Compared with free flaps, submental flap reconstruction was associated with significantly reduced total operative time and duration of hospitalization. Submental flaps were significantly less likely to require revision debulking procedures compared with latissimus dorsi flaps and free flaps. There was also 100% flap survival. However, a submental flap may not be available for use in all situations, specifically if its vascular supply has been damaged. This is often the case in patients who have previously undergone neck dissection or prior reconstructive procedures.

Microvascular Free Flap Reconstruction

Contemporary reconstructive literature demonstrates a trend toward more frequent use of free tissue transfer for repair of the lateral skull base.^{22,23} The defect volume, maximum attainable flap size and thickness, comparable tissue types and pedicle length are important initial considerations when choosing the appropriate free flap. Hanasono et al showed prior surgery, preoperative radiation therapy, and postoperative chemotherapy were the only factors associated with the use of free tissue transfer.⁸ Finally, the reconstructive surgeon should be aware of certain contraindications to the use of free flaps which include severe peripheral vascular disease, lack of sufficient recipient vessels, medical instability, and the need for vasopressors.

Several recent studies have compared outcomes using free flaps versus local or regional flaps in skull base reconstruction. Neligan et al studied a group of 90 patients, revealing a wound-related complication in 36% of patients who underwent a pedicled flap versus only 10% of patients repaired with free flaps.²⁴ The overall complication rate for local and free flaps was 33.8 and 33.5%, respectively, whereas the pedicled flap group complication rate was 75%. A study by Heth et al showed patients undergoing repair of anterior and anterolateral skull base defects with local flaps had a higher rate of acute perioperative issues as well as late wound breakdown than those undergoing free tissue transfer.²⁵ Their findings were attributed to cases of compromised wound healing, prior radiation therapy, or those patients undergoing concomitant radiation therapy.

Rectus Abdominis Flap

Traditionally, the rectus abdominis free flap was the workhorse for lateral skull base reconstruction as it can provide both skin and muscle. Blood supply comes from the deep inferior epigastric artery originating from the external iliac vessels just above the inguinal ligament. The flap is harvested with the patient in the supine position, and the donor site can be closed primarily. It is possible to capitalize on the rich vascular supply of the overlying abdominal wall skin and subcutaneous tissues to individually customize a soft, pliable, vascular cork of deepithelialized subcutaneous fat for the more central recesses of the ablation defect.

Izquierdo et al were one of the first to point out that the myocutaneous design is useful to enable closure of cutaneous defects while the muscle provides contour from hollowing if a craniotomy was performed.²⁶ In a series of 65 patients with either scalp or lateral temporal bone defects, the rectus was utilized in 11 cases (nine of which were specific to the lateral temporal bone).²⁷ All free flaps were transferred successfully. Their overall major and minor complication rates were 14.7% and 19.1%, respectively, which is consistent with other published series. Only one case of abdominal wall hematoma occurred from the rectus harvest site. They concluded a major advantage of this flap is the lengthy pedicle for access to donor vessels of the neck. Yet, the potential morbidity associated with rectus free flaps has steered reconstructive surgeons away from this option over the years. Abdominal herniation, as mentioned, can occur if the rectus abdominis muscle is removed below the arcuate line.

Anterolateral Thigh Flap

Compared with the rectus abdominis flap, the anterolateral thigh (ALT) flap offers just as large skin paddle volume and a muscle component from the vastus lateralis that can cover nearly any skull base defect. Blood supply is delivered to the ALT from the descending branch of the lateral femoral circumflex artery. Saphenous vein grafts, harvested from the same donor site incision as the ALT, can be used when the vascular pedicle length is inadequate to reach recipient vessels. ►Fig. 3 shows the anatomy of the ALT flap. When multiple defects are present, the ALT can be separated into two distinct skin paddles based on separate vascular perforators.²⁸ In cases where only one cutaneous perforator exist, but more than one skin paddle is needed, the intervening segment of skin can be de-epithelialized.

The promise of the ALT flap was demonstrated in a case series from MD Anderson Cancer Center of 34 consecutive patients with tumors involving the skull base who underwent reconstruction with an ALT free flap.²⁹ Five patients had exclusively a lateral skull base defect in addition to 10 others who either suffered from ALT or lateral-posterior wounds. The overall complication rate was 29%, and there were no flap losses. Nerve grafts ($n = 6$) and fascial slings ($n = 14$) for facial reanimation were performed using the lateral femoral cutaneous nerve and fascia lata from the same donor site as the ALT. The authors postulated that by harvesting the flap and graft(s) simultaneously with the resection, an average of 3 hours per case was saved.

Facial Reanimation

Repair and rehabilitation of facial nerve deficits are complex issues that deserve attention when discussing lateral temporal bone resections. Static reanimation procedures are safe and can be effective when performed concurrently with the ablative

surgery.³⁰ When facial nerve paralysis existed preoperatively, the patient should be evaluated for brow ptosis, ectropion, lagophthalmos and facial asymmetry. Depending on which of those deformities are present, the patient may be a candidate for direct browlift, lateral canthoplasty, upper eyelid gold weight placement and static reanimation with a fascial sling.

Nerve repair may be required depending on the situation of the defect. If a functioning facial nerve was sacrificed during the resection or facial nerve paralysis has been present for < 12 months, it is possible to reconstruct the facial nerve using cable nerve grafts as long as the proximal and distal ends can be located. Concurrent reconstruction with free tissue transfer offers nerve grafts within the operative field: the nerve to the rectus muscle from the rectus abdominis flap and the nerve to vastus lateralis from the ALT flap. It is best to perform these cable nerve grafts at the time of the resection because the procedure is fraught with potential complications when performed in a delayed manner following radiation therapy.

Complications of Lateral Skull Base Reconstruction

There are complications inherent to each type of reconstructive option, from simple primary closure to complex free tissue transfer. Most complications of the lateral skull base tend to be minor wound healing issues and are addressed with local wound care.³¹ However, wound dehiscence, bone exposure, and the need for secondary closure can occur. These may result from excessive tension, harvesting a flap inadequate for defect coverage or compromised recipient skin vasculature from previous surgery or irradiation. When bone and dura are involved, the issues can become more complex and present the potential risk of neurologic sequelae such as meningitis.

If the wound size is small, the wound may be left to granulate. For larger wounds, the application of a negative pressure dressing can be helpful to stimulate granulation tissue, clear infection, and aid in tissue contraction.³² Synthetic products, such as titanium or hydroxyapatite, can be used to cover dural or bony defects. However, some studies have suggested high rates of infection with synthetic products so caution must be exercised when choosing these as an option.³³ Radiation contributes to implant exposure and infection rates.

Since the majority of patients undergoing free tissue transfer have had prior treatment, whether primary radiation therapy or surgery with concurrent chemoradiation, the wound bed is prone to poor healing. Osteoradionecrosis of the skull base can occur which complicates reconstruction. Free flap success rates are similar to when used in other areas of the head and neck with expectations that complete flap loss should occur in < 5% of all patients.³⁴ Whereas CSF leak rates have been reported in up to 20% of resections involving dura, the use of larger myocutaneous flaps have helped curb that high rate.³⁵ Diagnosis is primarily clinical and can be confirmed by analyzing the fluid for glucose and β -2 transferrin. The majority of postoperative CSF leaks close spontaneously in 3 to 4 weeks with conservative management such as pressure dressings and lumbar drains. However, some authors support early surgical intervention for iatrogenic CSF leaks.³⁶

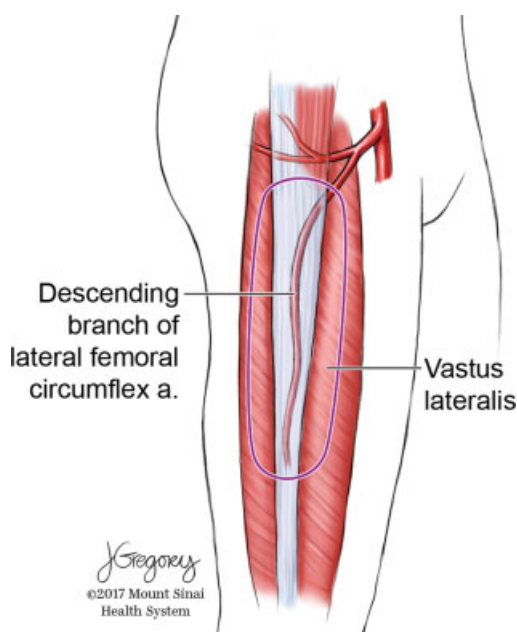


Fig. 3 Anatomical drawing of the anterolateral thigh free flap (Artwork courtesy of Jill K. Gregory from the Mount Sinai Health System).

Conclusion

Reconstruction of lateral skull base defects proves to be a complex task given its intricate three-dimensional morphology. Patient comorbidities, volume, and size of the defect, as well as surgeon experience all factor into the decision for locoregional versus free tissue transfer reconstruction. Regardless of the technique elected, the overall goals of reconstruction remain the same: preservation of function, restoration of cosmesis, and avoidance of morbidity.

Conflict of Interest

None.

Acknowledgment

We would like to thank Jill Gregory, senior medical illustrator, for contributing artwork to this article.

References

- Imola MJ, Sciarretta V, Schramm VL. Skull base reconstruction. *Curr Opin Otolaryngol Head Neck Surg* 2003;11(04):282–290
- Moyer JS, Chepeha DB, Teknos TN. Contemporary skull base reconstruction. *Curr Opin Otolaryngol Head Neck Surg* 2004;12(04):294–299
- Costa H, Cerejo A, Baptista A, et al. The galea frontalis myofascial flap in anterior fossa CSF leaks. *Br J Plast Surg* 1993;46(06):503–507
- Spinelli HM, Persing JA, Walser B. Reconstruction of the cranial base. *Clin Plast Surg* 1995;22(03):555–561
- Sinha UK, Johnson TE, Crockett D, Vadapalli S, Gruen P. Three-layer reconstruction for large defects of the anterior skull base. *Laryngoscope* 2002;112(03):424–427
- Rosenthal EL, King T, McGrew BM, Carroll W, Magnuson JS, Wax MK. Evolution of a paradigm for free tissue transfer reconstruction of lateral temporal bone defects. *Head Neck* 2008;30(05):589–594
- Patel NS, Modest MC, Brobst TD, et al. Surgical management of lateral skull base defects. *Laryngoscope* 2016;126(08):1911–1917
- Hanasono MM, Silva AK, Yu P, Skoracki RJ, Sturgis EM, Gidley PW. Comprehensive management of temporal bone defects after oncologic resection. *Laryngoscope* 2012;122(12):2663–2669
- Marzo SJ, Benschoter B, Leonetti JP. Contemporary options for lateral skull base reconstruction following tumor extirpation. *Curr Opin Otolaryngol Head Neck Surg* 2011;19(05):330–334
- Panje WR. Myocutaneous trapezius flap. *Head Neck Surg* 1980;2(03):206–212
- Marzo SJ, Leonetti JP, Petruzzelli CJ, Vandevender D. Closure of complex lateral skull base defects. *Otol Neurotol* 2005;26(03):522–524
- Haas F, Weiglein A, Schwarzl F, Scharnagl E. The lower trapezius musculocutaneous flap from pedicled to free flap: anatomical basis and clinical applications based on the dorsal scapular artery. *Plast Reconstr Surg* 2004;113(06):1580–1590
- Pallua N, Machens HG, Rennekampff O, Becker M, Berger A. The fasciocutaneous supraclavicular artery island flap for releasing postburn mentosternal contractures. *Plast Reconstr Surg* 1997;99(07):1878–1884, discussion 1885–1886
- Pallua N, Magnus Noah E. The tunneled supraclavicular island flap: an optimized technique for head and neck reconstruction. *Plast Reconstr Surg* 2000;105(03):842–851, discussion 852–854
- Chiu ES, Liu PH, Friedlander PL. Supraclavicular artery island flap for head and neck oncologic reconstruction: indications, complications, and outcomes. *Plast Reconstr Surg* 2009;124(01):115–123
- Emerick KS, Herr MW, Lin DT, Santos F, Deschler DG. Supraclavicular artery island flap for reconstruction of complex parotidectomy, lateral skull base, and total auriculectomy defects. *JAMA Otolaryngol Head Neck Surg* 2014;140(09):861–866
- Gal TJ, Kerschner JE, Futran ND, et al. Reconstruction after temporal bone resection. *Laryngoscope* 1998;108(4 Pt 1):476–481
- Resto VA, McKenna MJ, Deschler DG. Pectoralis major flap in composite lateral skull base defect reconstruction. *Arch Otolaryngol Head Neck Surg* 2007;133(05):490–494
- Martin D, Baudet J, Mondie JM, Peri G. [The submental island skin flap. A surgical protocol. Prospects of use]. *Ann Chir Plast Esthet* 1990;35(06):480–484
- Howard BE, Nagel TH, Donald CB, Hinni ML, Hayden RE. Oncologic safety of the submental flap for reconstruction in oral cavity malignancies. *Otolaryngol Head Neck Surg* 2014;150:558–562
- Howard BE, Nagel TH, Barrs DM, Donald CB, Hayden RE. Reconstruction of lateral skull base defects: a comparison of the submental flap to free and regional flaps. *Otolaryngol Head Neck Surg* 2016;154(06):1014–1018
- Thurnher D, Novak CB, Neligan PC, Gullane PJ. Reconstruction of lateral skull base defects after tumor ablation. *Skull Base* 2007;17(01):79–88
- Moncrieff MD, Hamilton SA, Lamberty GH, et al. Reconstruction options after temporal bone resection for squamous cell carcinoma. *J Plast Reconstr Aesthet Surg* 2007;60(06):607–614
- Neligan PC, Mulholland S, Irish J, et al. Flap selection in cranial base reconstruction. *Plast Reconstr Surg* 1996;98(07):1159–1166, discussion 1167–1168
- Heth JA, Funk GF, Karnell LH, et al. Free tissue transfer and local flap complications in anterior and anterolateral skull base surgery. *Head Neck* 2002;24(10):901–911, discussion 912
- Izquierdo R, Leonetti JP, Origitano TC, al-Mefty O, Anderson DE, Reichman OH. Refinements using free-tissue transfer for complex cranial base reconstruction. *Plast Reconstr Surg* 1993;92(04):567–574, discussion 575
- O'Connell DA, Teng MS, Mendez E, Futran ND. Microvascular free tissue transfer in the reconstruction of scalp and lateral temporal bone defects. *Craniomaxillofac Trauma Reconstr* 2011;4(04):179–188
- Kimata Y, Uchiyama K, Ebihara S, Nakatsuka T, Harii K. Anatomic variations and technical problems of the anterolateral thigh flap: a report of 74 cases. *Plast Reconstr Surg* 1998;102:1517–1523
- Hanasono MM, Sacks JM, Goel N, Ayad M, Skoracki RJ. The anterolateral thigh free flap for skull base reconstruction. *Otolaryngol Head Neck Surg* 2009;140(06):855–860
- Watts TL, Chard R, Weber SM, Wax MK. Immediate eye rehabilitation at the time of facial nerve sacrifice. *Otolaryngol Head Neck Surg* 2011;144(03):353–356
- Iseli TA, Rosenthal EL. Reconstruction of periauricular and temporal bone defects. *Facial Plast Surg Clin North Am* 2009;17(02):253–262
- Rosenthal EL, Blackwell KE, McGrew B, Carroll WR, Peters GE. Use of negative pressure dressings in head and neck reconstruction. *Head Neck* 2005;27(11):970–975
- Wong RK, Gandolfi BM, St-Hilaire H, Wise MW, Moses M. Complications of hydroxyapatite bone cement in secondary pediatric craniofacial reconstruction. *J Craniofac Surg* 2011;22(01):247–251
- Frederick JW, Sweeny L, Carroll WR, Peters GE, Rosenthal EL. Outcomes in head and neck reconstruction by surgical site and donor site. *Laryngoscope* 2013;123(07):1612–1617
- Chiu ES, Kraus D, Bui DT, et al. Anterior and middle cranial fossa skull base reconstruction using microvascular free tissue techniques: surgical complications and functional outcomes. *Ann Plast Surg* 2008;60(05):514–520
- Savva A, Taylor MJ, Beatty CW. Management of cerebrospinal fluid leaks involving the temporal bone: report on 92 patients. *Laryngoscope* 2003;113(01):50–56