

A graded approach to the achievement of natural appearing, aesthetically pleasing results in facelift patients

Yadranko Ducic, MD, FRCS(C)¹, Peter A. Hilger, MD, FACS²

¹Department of Otolaryngology-Head and Neck Surgery, University of Texas SouthWestern Medical Center in Dallas, TX, Division of Otolaryngology and Facial Plastic Surgery, John Peter Smith Hospital, Fort Worth, TX; ²Department of Otolaryngology-Head and Neck Surgery, University of Minnesota, Minneapolis, MN; USA

Accepted:

Abstract

The scope of facelift surgery (or rhytidectomy) has undergone numerous significant advances over the past ten years. Although placing more technical demands on surgeons, the results have been quite rewarding. Careful knowledgeable dissection after a diligent preoperative analysis will consistently give the patient worthwhile rejuvenation. The authors outline their method of achieving natural appearing aesthetically pleasing facial rejuvenation in the patient presenting for facelift surgery. They detail an algorithm that may be useful for surgeons, who are cognizant of advanced facelift techniques, to consider.

Introduction

It is difficult to assign the origin of rhytidectomy to any one person in particular. It seems that this operation emerged concurrently around the turn of the century in a number of centers around Europe, as a result of the extraordinary vision of a number of fine surgeons, including Joseph, Lexer, Hollander and Noel¹⁻⁴. These early procedures essentially constituted 'minilifts', with skin undermining limited to one to two centimeters circumferentially about the ear. Consequently, results were often short-lived and somewhat unimpressive for the most part. Until relatively recently, the major evolutionary change in facelift surgery consisted almost entirely of an extension of the skin lift. Although

enabling more dramatic results to be achieved, this procedure was likewise often inadequate, as a result of the 'mask-like' artificial facial rejuvenation that was achieved.

Over the past decade, we have witnessed an explosion in the demand for cosmetic surgery. Together with an increase in patient acceptability has come a desire for a more natural appearing, longer lasting facial rejuvenation. Facelift surgery has attempted to meet this challenge by focusing the surgeon's efforts on deeper planes of dissection and by more often than not, addressing the facial rejuvenation effort with a number of ancillary aesthetic procedures.

Mitz and Peyronie are often credited with the first thoughtful anatomical description of the superficial musculoaponeurotic system (SMAS)⁵.

From these simple anatomical studies emerged the realization that the key to achieving more aesthetically pleasing results lies in performing the operation in deeper planes of dissection, while limiting the amount of skin undermining. Owsley, Aston and Hamra have outlined variations in this basic theme, demonstrating gratifying results with limited morbidity in large numbers of patients⁶⁻⁸.

Although technically much more demanding, the patient outcomes achieved with the application of so-called deep plane rhytidectomy techniques have been well worth the effort. We feel that it is important to modify the operation performed, based upon individual patient needs and desires. Thus, we have developed a systematic approach to this patient population, which is simple to apply and associated with very pleasant, natural appearing facial rejuvenation. In this article, we will outline our successful approach to this patient population.

Technique

Preoperative markings are, as usual, performed with the patient in the sitting position. We routinely delineate the jowls, platysmal bands, and deposits of submental fat. At the time of surgery, we routinely give our patients intravenous steroids (Decadron 10 mg intravenously) and antibiotics (Cefazolin 1 g intravenously or equivalent if allergic). Although this is a procedure that may be safely performed under sedation anesthesia, we prefer that a general anesthetic be administered to our patients. The length of time required to perform the facelift and any ancillary procedures may become somewhat long, justifying the safety and comfort of a general anesthetic. Nerve blocks are performed with 1% lidocaine with 1 in 100,000 epinephrine solution. Subcutaneous and subSMAS infiltration is then performed with 0.5% lidocaine with 1 in 100,000 epinephrine solution infiltrated with a 27-gauge spinal needle.

Initially, an endoscopic browlift is performed in the usual manner, if required. Next, conservative upper blepharoplasties are performed prior to the onset of the swelling that will ac-

company the deeper planes of facelift dissection.

At this point, lower eyelid surgery is entertained. Transconjunctival blepharoplasties with conservative fat excision are done with the use of fine Teflon-tipped electrocautery units, which are commercially available. These are useful procedures in patients with fat pseudoherniation, but little skin excess. Trichloroacetic acid lower lid peel and carbon dioxide laser skin resurfacing are useful adjuncts, which may be performed safely at the completion of the entire procedure to treat any fine superficial rhytids of the lower lid skin. If there is an apparent increase in orbital volume with major descent inferiorly of the orbicularis oculi muscle, then a standard incision is made for an external lower blepharoplasty, 2-3 mm below the inferior lash line. A skin-only flap is elevated for a distance of 5-7 mm. Next, the orbicularis muscle is incised, taking care to preserve the fast twitch fibers of the pretarsal orbicularis oculi (superior 4-5 mm of orbicularis muscle), and the submuscular plane is entered at this point. Dissection proceeds to the inferior edge of the muscle and will later be connected with the subSMAS dissection of the facelift. The redraped skin-muscle flap is conservatively excised, and a sleeve of orbicularis muscle is suspended via the upper blepharoplasty incision with a 5.0 PDS or vicryl suture (Fig. 1). The lower blepharoplasty incision is closed at completion of the rhytidectomy with a running 6.0 fast absorbing gut suture.

At this point, a limited 1.0 cm submental incision, supplemented on occasion with 0.5 cm incisions behind the earlobes bilaterally, is then made to allow the introduction of liposuction cannulas of appropriate dimension. We use 3-5 mm cannulas and perform conservative suction-assisted lipectomy directed away from the skin surface. It is important not to be overly aggressive at this junction, in order to avoid a skeletonized 'lollipop' appearance. If platysmal banding is present, the initial submental incision is extended for an additional 2.0 cm to give access to the medial ends of the platysma. These are reconstituted in the midline with a 3.0 vicryl or mersilene suture. The muscles are brought together inferiorly to the level of the larynx (Fig. 2). Long facelift scissors are invaluable at this

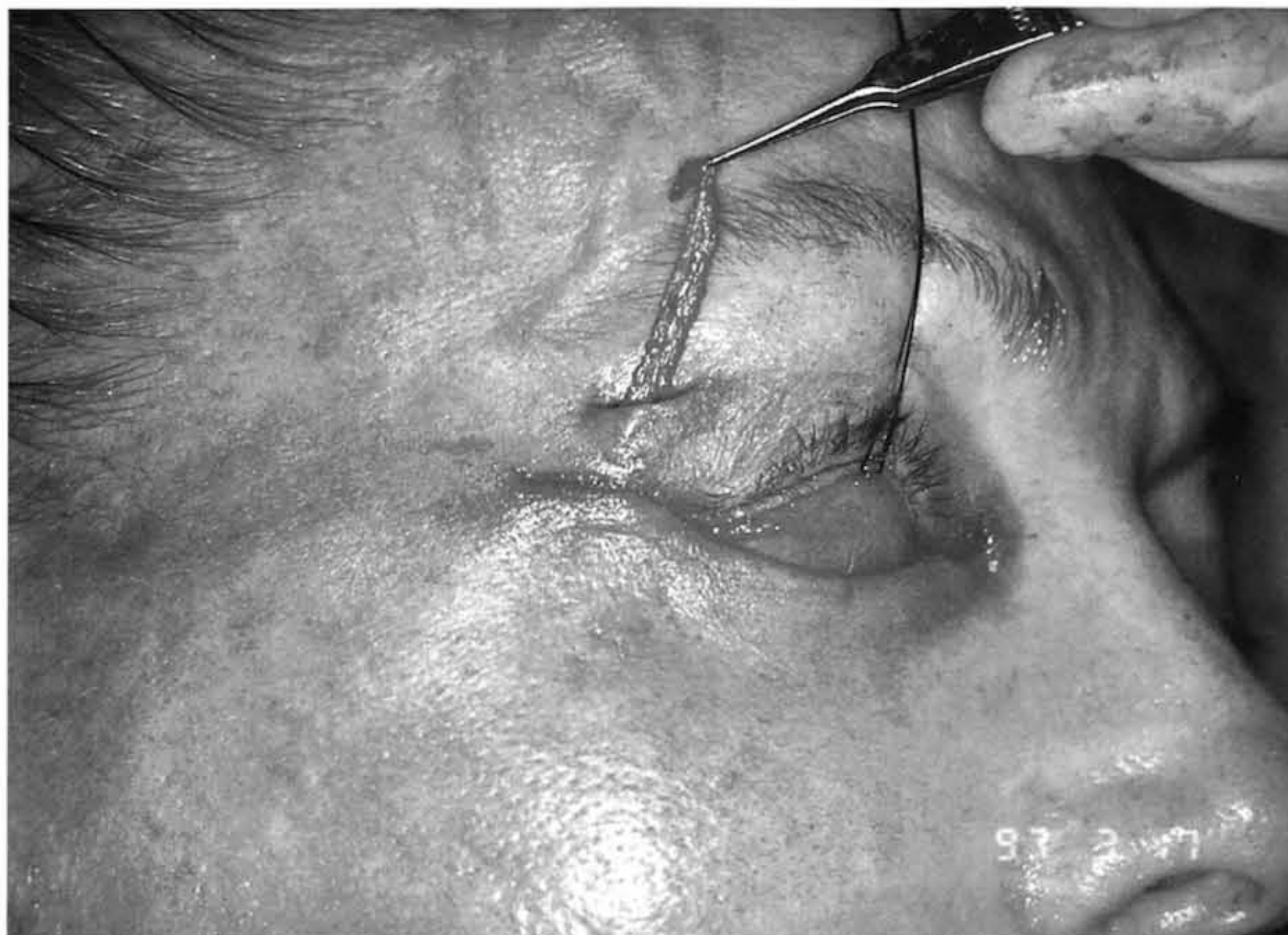

Fig. 1. External blepharoplasty has been performed and a sling of orbicularis oculi muscle has been developed for suspension. Access for the suspension is achieved via an upper blepharoplasty type incision.

junction to effect elevation of the cervical skin between the two sternocleidomastoid muscles, and in a plane superficial to the platysma muscle.

At this juncture, the facelift incision is fashioned to pass from the temporal area (2-3 cm into the hairbearing scalp), inferiorly either retroragally or pretragally (males and patients with a very well-defined preauricular crease), around the lobule, hugging the postauricular crease, and finally extending postero-inferiorly into the hairbearing scalp just superior to the level of the easily visible postauricular muscle. The postauricular muscle may be visualized by anterior traction on the auricle. It serves both as a reliable indicator of the appropriate level at which to place the postauricular incision into the scalp, and as a convenient and secure fixation point for the postauricular SMAS sling that will be developed later in the course of the operation. In patients who have a very limited temporal tuft of hair, the temporal incision may be extended around the temple tuft of hair (preserving it) and then back into the temple hairline at a more superior level.

In the temporal area, the anatomical abnormality will determine the plane of dissection. If there is significant ptosis of the lateral brow, dissec-

tion should proceed just superficial to the deep temporal fascia (superior to the level of the superficial temporal fat pad) to the superolateral orbital rim. The periosteum of the rim (superior to the fixed point of attachment of the lateral canthal tendon), as well as the periosteal attachments at the level of the conjoint tendon, all need to be fully released to effect brow mobility. If brow position is adequate, but superficial rhytids of the lateral periorbital area need to be addressed, then a subcutaneous dissection, immediately below the level of the temporal hair follicles needs to be carried out (Fig. 3). In either case, the developed temporal flap will be fixated to the deep temporal fascia just superior to the auricle with a 3.0 vicryl, PDS or mersilene suture. Minimal removal (0.5-1.0 cm) of hairbearing scalp in this area is the rule rather than the exception.

In the cheek area, a limited subcutaneous dissection is performed for a distance of 3 cm anterior to the auricle (Fig. 4). The SMAS is next incised just superior to the level of the zygomatic arch in its posterior one half, and vertically approximately 0.5-1.0 cm in front of the auricle. Maintaining a thin remnant of undisturbed SMAS in front of the ear allows for preservation

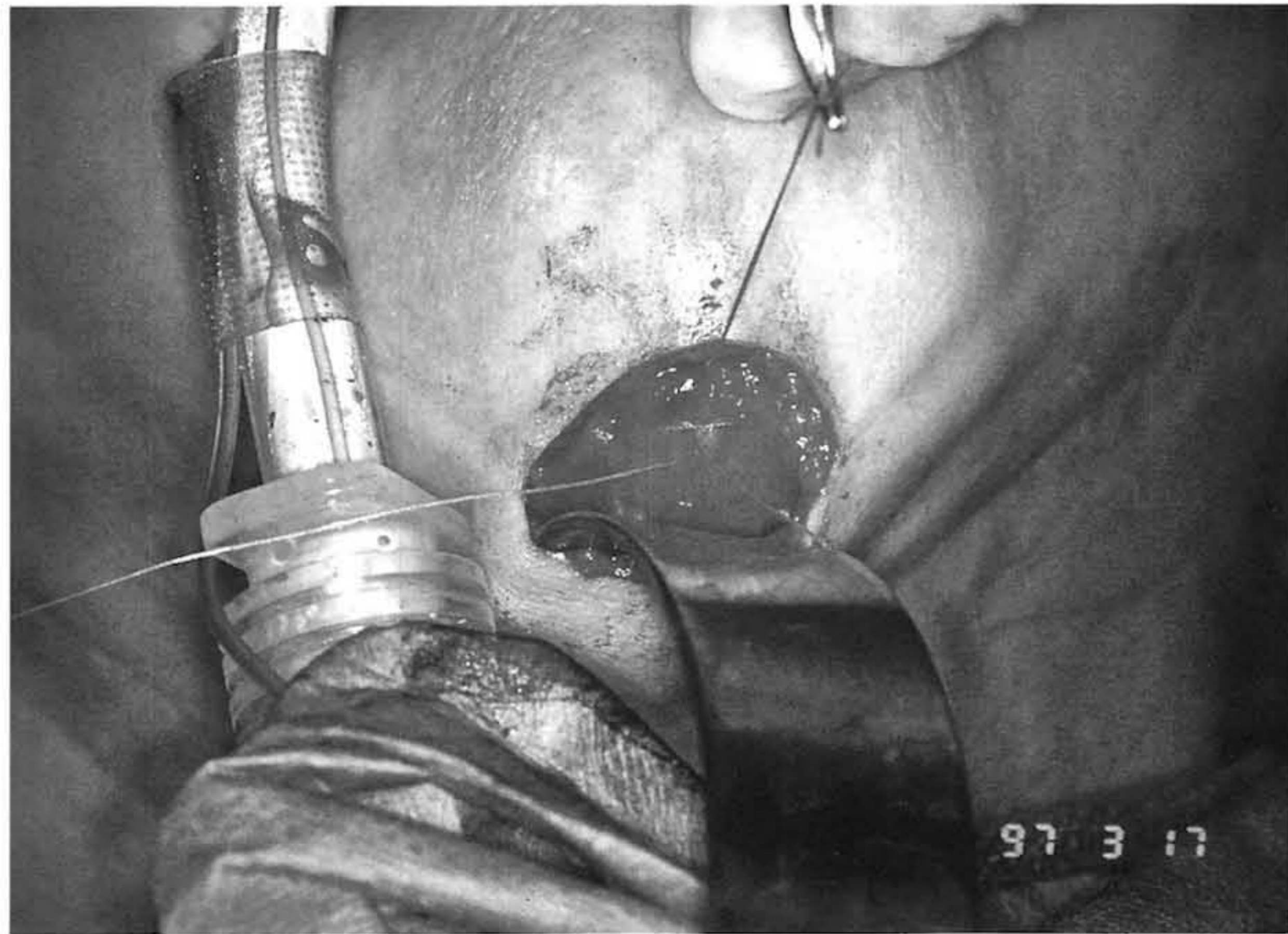


Fig. 2. Platysma plication is performed via an extended submental incision. A superior traction suture is often quite helpful.

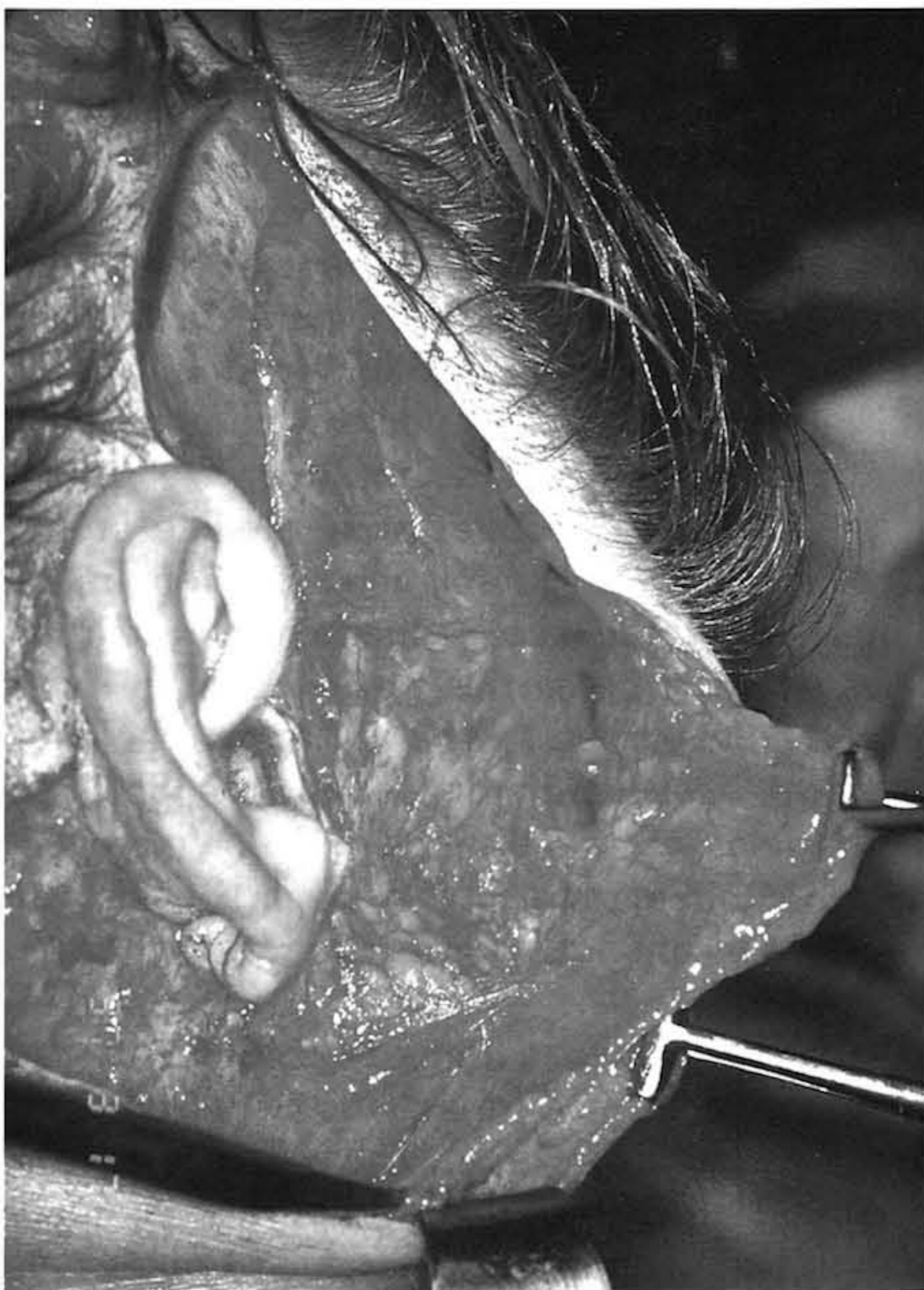

Fig. 3. This patient required subcutaneous dissection in the temporal area. The limit of this dissection is demonstrated.

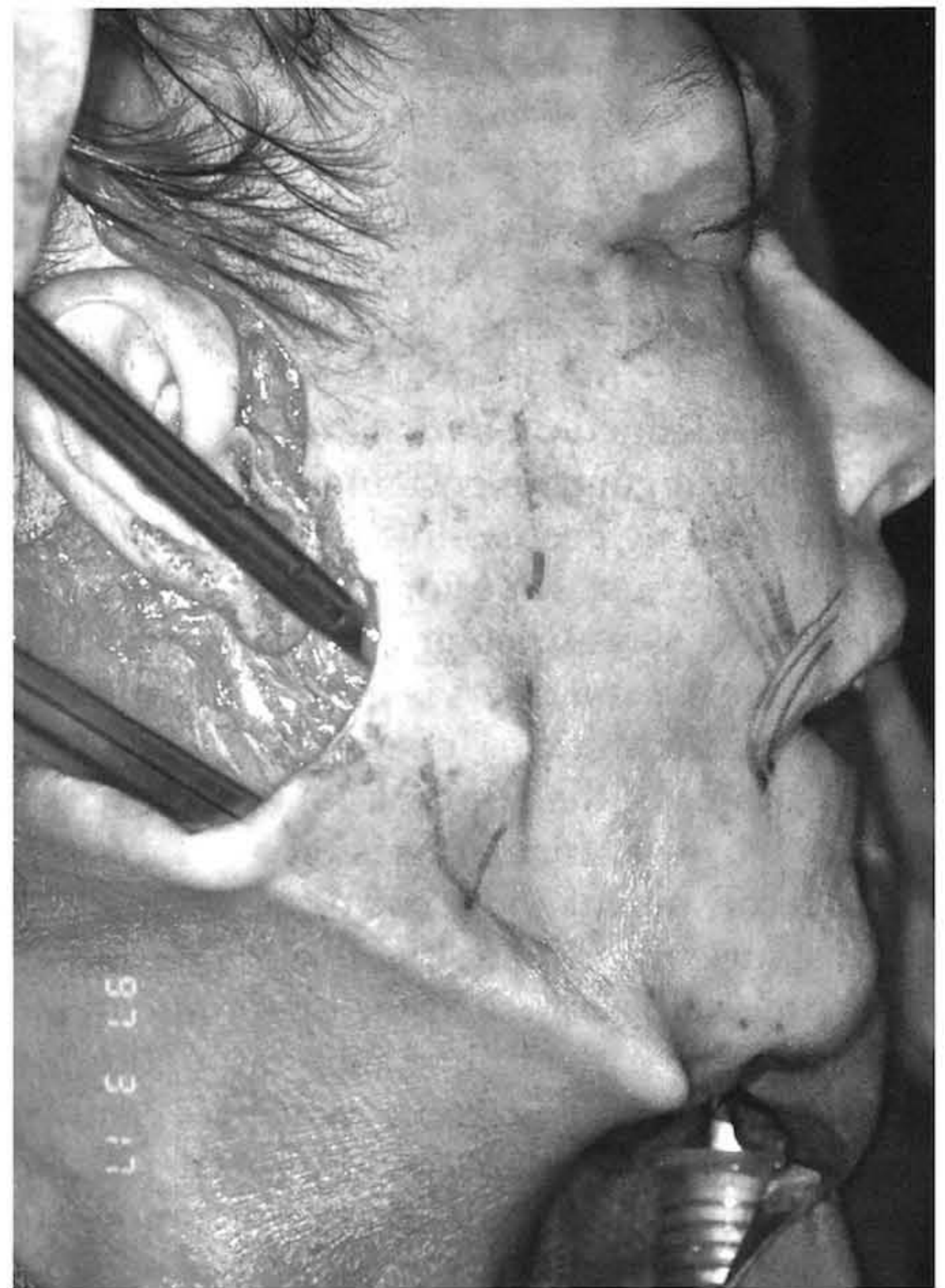

Fig. 4. The limit of the subcutaneous dissection overlying the cheek is compared to cervical skin elevation.

of the natural contours that are otherwise difficult to reform with surgery. The SMAS flap is elevated sharply off the superficial surface of the parotid gland with scalpel dissection. Staying within the proper plane of dissection at this point will result in a bloodless dissection. Once the anterior edge of the parotid gland has been reached, scissors are used to bluntly open the remainder of the subSMAS plane. The branches of the facial nerve are often easily visible at this point in the dissection. This subSMAS dissection proceeds to the level of the zygomaticus muscles. These muscles are often visible and always palpable (Fig. 5). Further subcutaneous dissection into the area of the nasolabial fold is performed if necessary. At this point, the osteocutaneous ligaments overlying the body of the zygoma are fully released, and the subSMAS dissection is connected to the suborbicularis dissection (if orbicularis resuspension is required). If orbicularis descent is not an important issue for the patient, limited subcutaneous dissection superficial to the orbicularis may be helpful in rhytid effacement in this area.

We prefer to dissect subSMAS to the level of the zygomaticus and subplatysmal along the mandible (to the point on the mandible where the facial vessels crossover), while maintaining an intact relatively nondissected bridge in between. This serves three important purposes. Firstly, the ease and swiftness of the dissection is greatly expedited. Secondly, in dissecting the mid portion completely, one is often left with the problem of achieving symmetric suspension of the fat pad of Bichet, which can be difficult. Finally, by maintaining the intact bridge, a 'hammock-like' support is developed for the midface, which is quite natural in appearance but remarkably apt in terms of rejuvenation.

Limited subcutaneous dissection superficial to the sternocleidomastoid muscle is now performed. The SMAS flap is anchored to the deep temporal fascia superior to the auricle with a 2.0 vicryl, PDS or mersilene suture. A tongue of SMAS is then developed anterior to the auricle and fixated to the preauricular muscle. This results in a bidirectional pull, achieving a predominantly superolateral vector for midface suspension, while

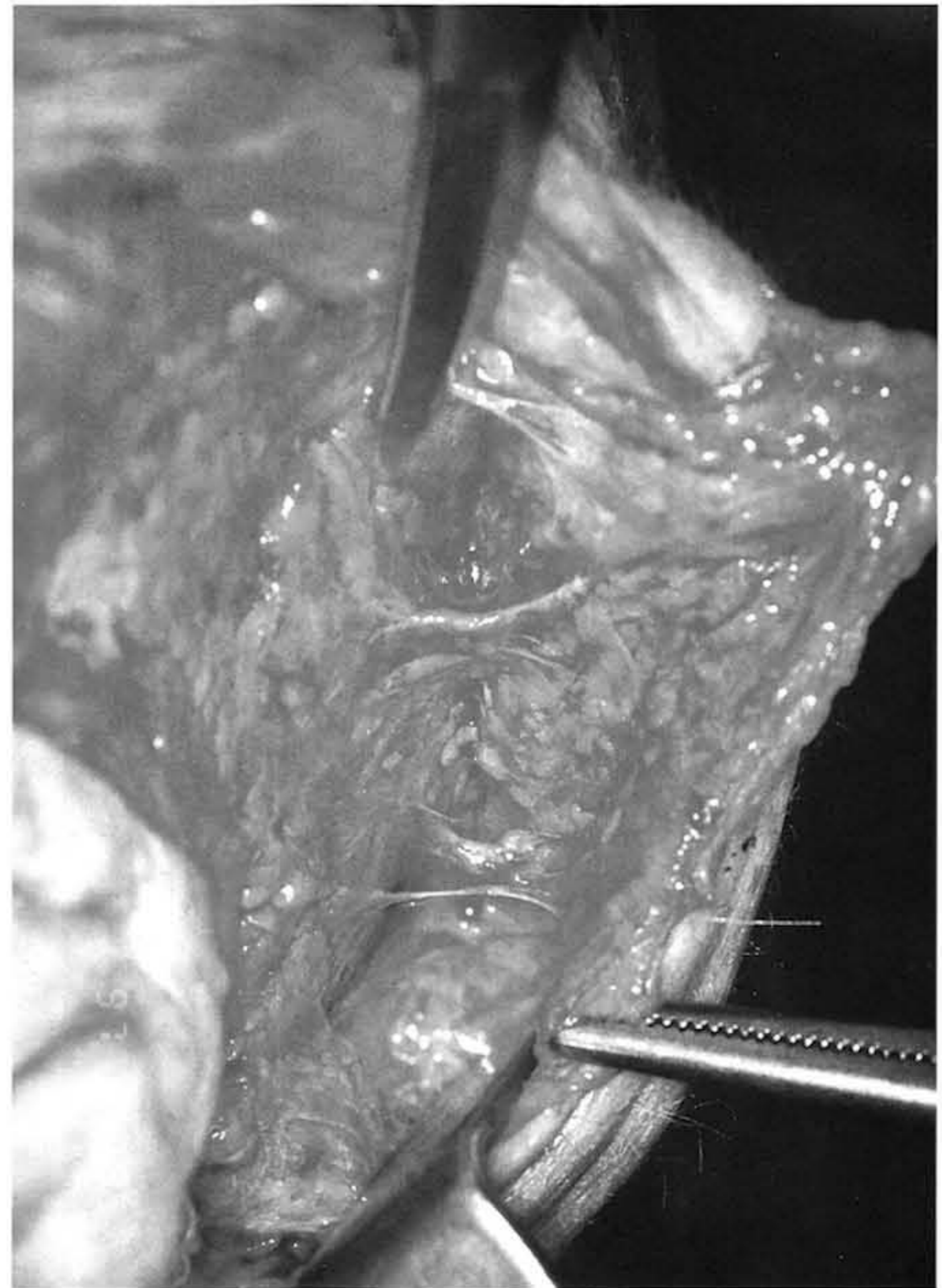


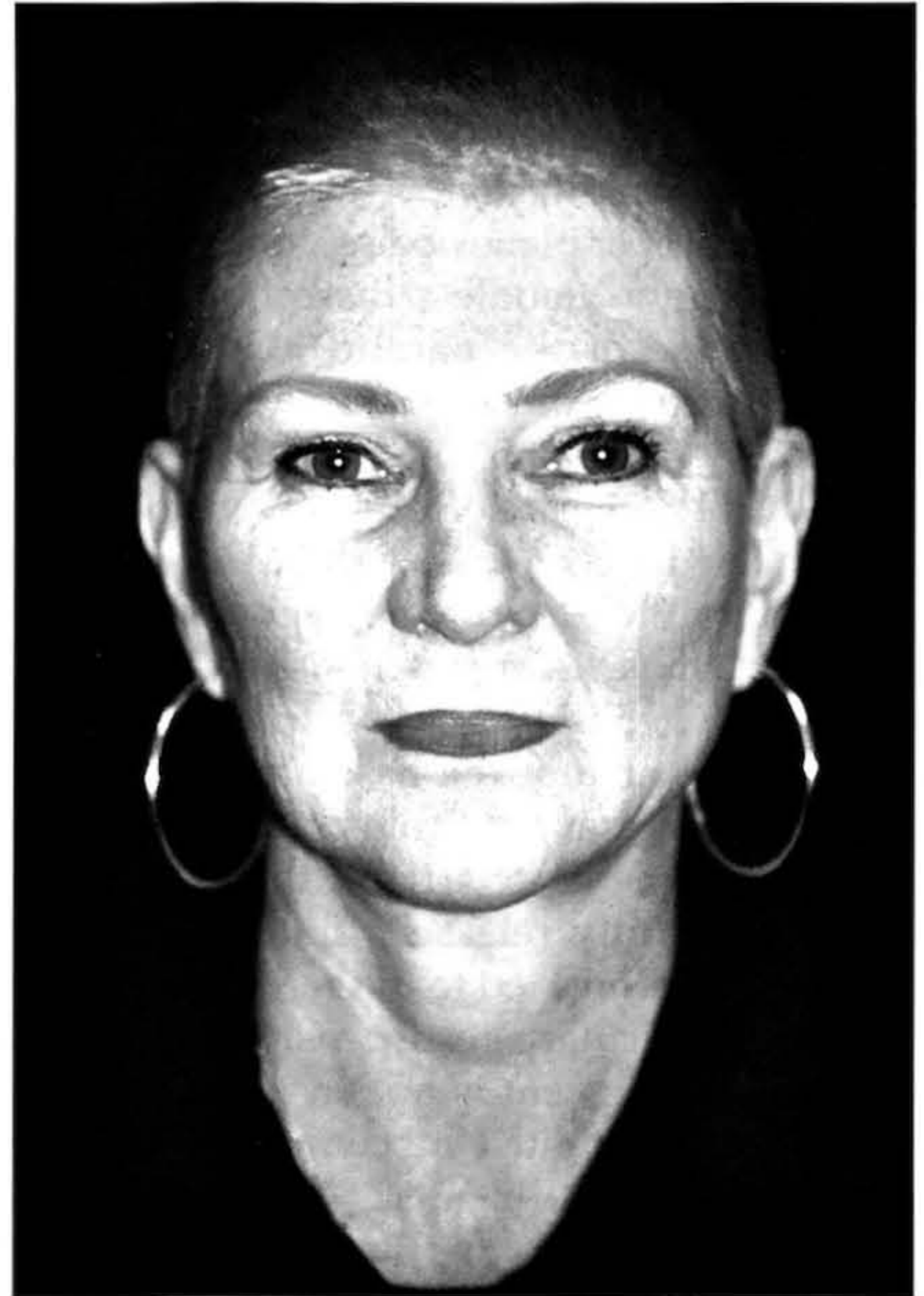Fig. 5. The limit of dissection is the zygomaticus muscle which is noted in the midportion of this Figure.

the mandibular contour is enhanced with a predominantly posterolateral vector. A small dimple often is noted just above the zygomatic arch, due to underlying fixation. This resolves completely with time. The skin is redraped and conservative trimming (often just 1-3 cm) ensues. The skin is closed in a tension-free manner after reconstitution of the hairline posteriorly, and maintenance of a normal appearing hairline temporarily, with 4.0 vicryl for the subcutaneous and running 5.0 nylon for the skin layers.

Drains are usually employed. Their role is, however, unproven in rhytidectomy. A bulky cotton dressing is applied for patient comfort. The patient is seen in the office the following day, at which point the drains are removed and a jaw bra elastic garment applied. This is to be worn continuously for two weeks and nightly for two weeks thereafter.

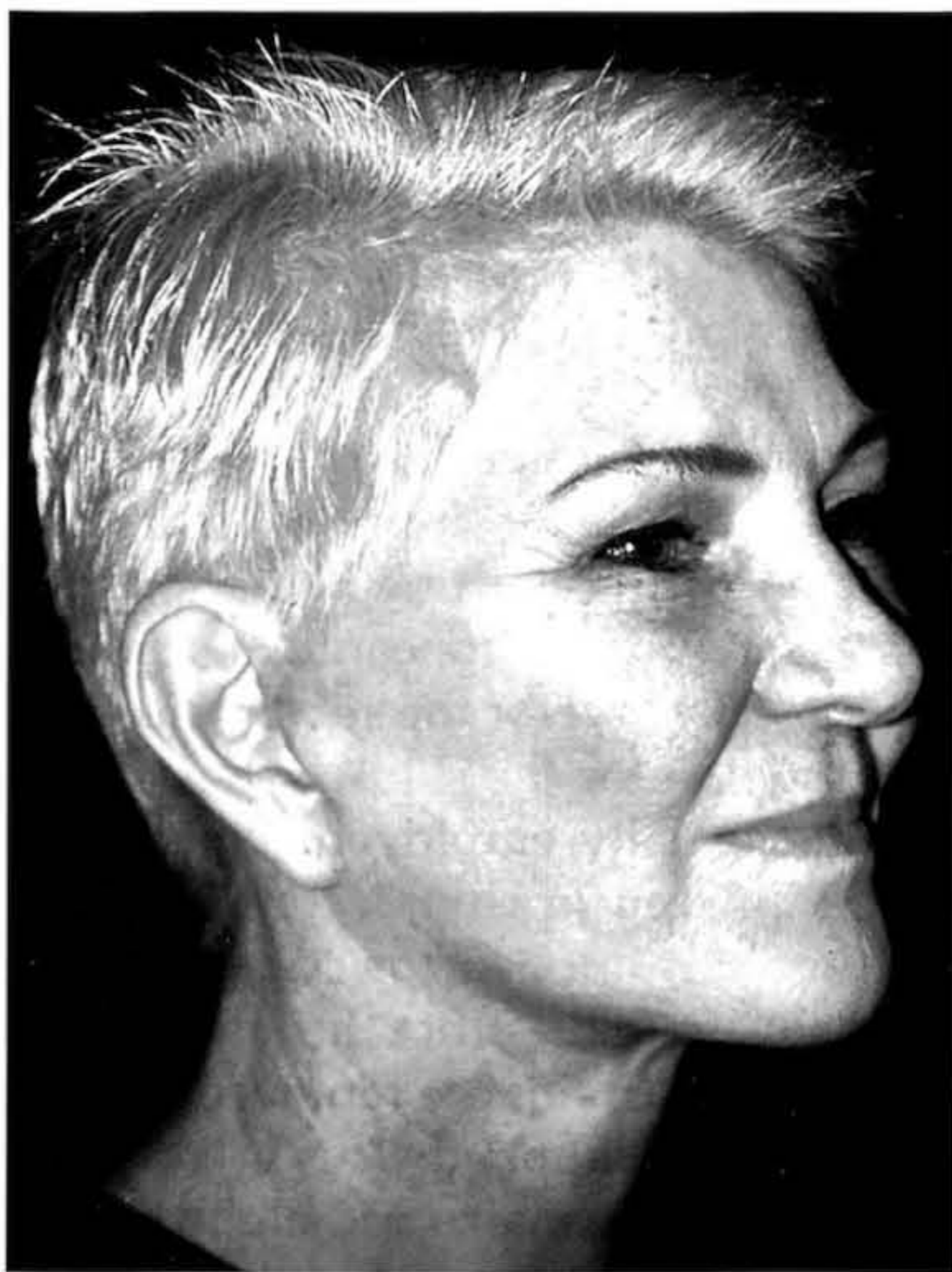

6




7

Figs. 6 and 7. Preoperative oblique and frontal views of a patient, demonstrating adequate brow arch and position, moderate cheek mound ptosis, and early jowling.



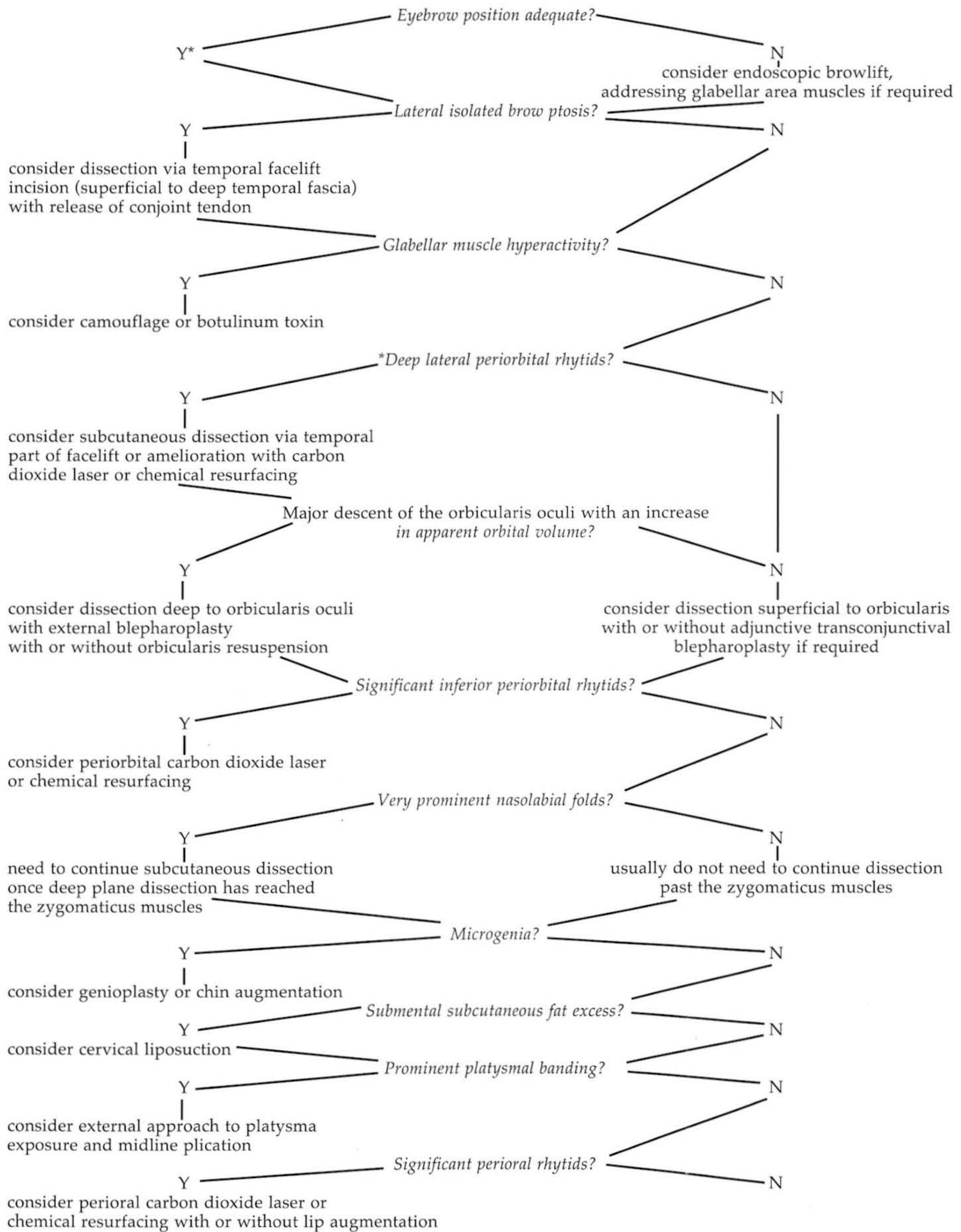
8



9

Figs. 8 and 9. Postoperative oblique and frontal views of same patient at six months, demonstrating natural appearing rejuvenation which is aesthetically pleasing. Note the positive effects of the midfacial 'hammock'.

Graded approach to the aging face algorithm



Discussion

Utilizing the technique outlined, we have been able to achieve dramatic, yet natural appearing facial rejuvenation in our facelift population over the past three years in over 50 patients (Figs. 6, 7, 8 and 9). We have not encountered any skin necrosis, hematoma, facial nerve palsy or other untoward outcome. All patients were able to achieve aesthetically pleasing results without the need for revisional surgery.

When analyzing the aging face, there is a need to be systematic and each subunit should be approached appropriately in order to effectively re-establish the aesthetic balance of the whole (see Algorithm).

We prefer to begin the analysis in the upper one-third of the face, looking specifically at the arch and position of the eyebrows, and the resting state of the glabellar area muscles (procerus and corrugator supercilii). In female patients, if the eyebrows are arched appropriately (with the peak of the arch midway between the lateral limbus and lateral canthus) and are situated slightly above the level of the orbital rim (in males, a flatter brow positioned at the level of the orbital rim is usually acceptable), then they do not need to be specifically addressed. Glabellar area hyperactivity in this circumstance should be addressed with camouflage techniques (collagen, Alloderm, fascia, etc.) or botulinum toxin injection. If, however, the brow arch is flattened and has drifted at or below the level of the superior orbital rim, brow position should be re-established with the adjunctive use of an endoscopic browlift. The reconstitution of an ideal arch is difficult to achieve with this procedure, but may be attempted by placing differing degrees of pull on the various fixation points. The procerus and corrugator muscles may now be surgically addressed (transected, partially resected) via the endoscope. The issue of how best to deal with these muscles remains unresolved. Subtotal muscular regrowth appears to be the rule with the passage of time when the muscles are simply transected, while aggressive muscular resection often leaves the patient with prolonged glabellar edema that is often as disfiguring as their initial problem. Often, however, the temporal

half of the brow descends as the initial manifestation of generalized brow ptosis. This may be ameliorated with elevation performed via the temporal part of the facelift dissection.

The analysis of the lower two-thirds of the face should begin with the evaluation of the periorbital area. Excess upper eyelid skin redundancy should be removed with a standard conservative upper blepharoplasty. Removal following any endoscopic forehead lift is the rule. If there is any doubt about the adequacy of remaining upper lid skin, upper blepharoplasty would be best deferred and instead performed as a delayed secondary office procedure in order to prevent lagophthalmos. Deep lateral periorbital wrinkling ('crow's feet') may be addressed with a subcutaneous dissection in the temporal area, or ameliorated with carbon dioxide laser resurfacing or chemical peel. Finally, the degree of descent of the orbicularis oculi muscle should be evaluated. The need to address this problem at the time of facelift has been espoused by Hamra⁸. If this is felt to be a significant problem for the patient, an external blepharoplasty approach, with or without orbicularis resuspension, is warranted. This will result in a decrease in the apparent orbital volume and reverse one of the obvious stigmata of aging.

As one views the degree of cheek mound ptosis present, there is a need to determine whether the degree of concomitant nasolabial fold prominence may be adequately addressed by deep plane dissection to the level of the zygomaticus, or whether further subcutaneous dissection beyond that level will be required. Often, this may only be determined intraoperatively by establishing the amount of effacement of the nasolabial fold achieved by placing traction on the released SMAS flap. If this appears to be inadequate, then further dissection to the level of the nasolabial fold is warranted. This is achieved by passing from the subSMAS plane to the subcutaneous plane at the level of the anterior border of the zygomaticus muscles.

Next, attention should be directed toward the cervical contour. Associated microgenia should be corrected with orthognathic procedures with or without orthodontia, if there is a significant degree of malocclusion present. Vertical mental

height imbalance is best addressed with genioplasty. Simple augmentation mentoplasty is, however, the best option for the majority of this patient population. We prefer the use of any of a number of solid preformed medical grade silicone prostheses, which are widely available commercially.

Any submental fat excess should be removed with liposuction prior to addressing platysmal banding with submental exposure and midline plication. Perioral rhytids may be ameliorated with laser or chemical peeling at the time of the primary procedure. Lip augmentation is a valuable adjunct, which may be performed at the time of facelift surgery to enhance the overall rejuvenation achieved. It is especially valuable in helping to efface the peri-vermilion creases that develop with aging, and are exacerbated by cigarette smoking. No one procedure has proven ideal in the treatment of these deep rhytids, although significant improvement may be achieved.

Although a number of authors have espoused the benefits of routine subperiosteal face-lifting, we feel that this procedure may be best suited to revision cases where the initial procedure was a deep plane facelift, since sub-SMAS dissection in this patient population would be more difficult to perform safely⁹. In addition, in the patient with unusually heavy cheek mounds, this may be the only way of achieving worthwhile aesthetic rejuvenation. The surgeon must, however, prepare these patients for the alterations in the lateral canthal area that are often a by-product of subperiosteal release and appropriate suspension.

Traditional thought has held that simultaneous carbon dioxide or chemical peel resurfacing cannot be safely performed in areas of the face that had been undermined. There is no doubt that these additional procedures would compromise the vascularity of a flap undermined in the subcutaneous plane. However, the utilization of deeper planes of dissection with either the deep plane or subperiosteal facelifts, has allowed for simultaneous treatment of superficial rhytids

with resurfacing. We commonly utilize this as an adjunct in the periorbital and perioral areas. However, we feel that the added stress of caring for a full-face wounding of the skin, makes the recovery period substantially more difficult for many patients to cope with. Thus, we defer full-face resurfacing to a secondary setting, six to 12 months after a primary facelift.

Conclusions

The theoretical advantages of deeper planes of dissection have included a decrease in the incidence of skin slough, subcutaneous dimpling, and hematoma. We feel that the deeper planes of dissection also provide for an enhancement of the results that may be achieved in facelift surgery. We have found the outlined technique to be safe, fast, and simple to teach and learn. However, we would recommend that surgeons who have not performed advanced facelift techniques either enroll in enrichment courses or observe a knowledgeable colleague, prior to embarking on this type of surgery.

References

1. Joseph J: Plastic operation on protruding cheek. *Dtsch Med Wochenschr* 47:287, 1921
2. Lexer E: Zur Gesichtsplastik. *Arch Klin Chir* 92:749, 1910
3. Hollander E: Rhytidectomy: anatomical, physiological and surgical considerations. *Plast Reconstr Surg* 20:218, 1957
4. Noel A: *La Chirurgie Esthetique*. Clermont: Thiron et Cie, 1928
5. Mitz V, Peyronie M: The superficial musculoaponeurotic system in the parotid and cheek area. *Plast Reconstr Surg* 58:80, 1976
6. Owsley JQ: SMAS-platysma facelift. *Plast Reconstr Surg* 71:573, 1983
7. Aston SJ: Platysma muscle in rhytidoplasty. *Ann Plast Surg* 3:529, 1979
8. Hamra ST: The deep plane rhytidectomy. *Plast Reconstr Surg* 86:53, 1990
9. Ramirez OM, Maillard GF, Musolas A: The extended subperiosteal facelift: a definitive soft tissue remodeling for facial rejuvenation. *Plast Reconstr Surg* 88:227, 1991