

# Condylar Fractures

Raja Sawhney, MD, MFA<sup>a</sup>, Ryan Brown, MD<sup>b</sup>,  
Yadranko Ducic, MD, FRCS(C)<sup>c,d,\*</sup>

## KEYWORDS

• Condylar fractures • Mandible fractures • Endoscopic fracture repair

## KEY POINTS

- There is a role for both open and closed reduction in the treatment of condylar fractures.
- Using a thoughtful approach with an understanding of the pros and cons of each treatment option, applied individually to each patient fracture, leads to the best long-term outcomes while minimizing the sequelae associated with surgery.
- Careful unbiased critique of postoperative results with the goal of continually improving techniques and outcomes is, in the end, significantly beneficial to both patients and surgeons.

## OVERVIEW

No area of facial trauma elicits as much debate as the treatment of fractures of the condylar region. Optimal treatment seems to vary as much by surgical subspecialty as by treating surgeons themselves. Some of this variability is derived from surgeon comfort with different surgical techniques and approaches as well as concern for vital surrounding structures.<sup>1</sup> Earlier publications on the treatment of these types of fractures attempted to determine whether open or closed treatment is the optimal choice.<sup>2</sup> Recent discussions have shifted, with the understanding that both treatments have their indications. What is open for debate is when each option should be used.

Condylar fractures account for 20% to 62% of all mandibular fractures.<sup>3</sup> Traditionally, closed management has been the most advocated treatment. As new techniques were developed and a better understanding of the associated sequelae of closed reduction elicited, there was a trend toward more surgical reduction of the fracture. Rigid rules with fairly wide indications for the implementation of open approaches were proposed, but concerns arose regarding whether these rules were leading to

---

<sup>a</sup> Department of Otolaryngology–Head and Neck Surgery, University of Florida, 200 Southwest 62nd Boulevard, Suite B, Gainesville, FL 32607, USA; <sup>b</sup> Department of Head and Neck Surgery, Kaiser Permanente, 2045 Franklin Street, Denver, CO 80205, USA; <sup>c</sup> Department of Otolaryngology–Head and Neck Surgery, University of Texas Southwestern Medical Center, Dallas, TX, USA; <sup>d</sup> Otolaryngology and Facial Plastic Surgery Associates, 923 Pennsylvania Avenue, Suite 100, Fort Worth, TX 76104, USA

\* Corresponding author. Otolaryngology and Facial Plastic Surgery Associates, 923 Pennsylvania Avenue, Suite 100, Fort Worth, TX 76104.

E-mail address: [yducic@sbcglobal.net](mailto:yducic@sbcglobal.net)

unnecessary surgery, with increases in morbidity, surgical time, and risk to the facial nerve. A middle ground has developed, where there is an understanding of those patients who can be treated successfully with simple closed reduction and those better served with open reduction of their condylar fracture.

There are few absolute indications for the open treatment of condylar fracture. If adequate occlusion cannot be obtained through closed reduction, then open reduction is necessary. Most agree that condylar fractures in conjunction with significant comminuted midface fractures warrants condylar reduction. In difficult midface fractures, the intact mandible is used as a stable base from which to reset maxillary dentition, re-establish occlusion, and then rebuild the midface as a whole, in a bottom to top fashion.<sup>4</sup> By recreating appropriate occlusion, proper maxillary projection and width can be re-established.

Ellis and colleagues<sup>4</sup> maintain the need for open treatment in edentulous patients and in those missing significant posterior dentition. In these cases, closed reduction cannot adequately address the loss of vertical mandibular height that is normally re-established when appropriate posterior dentition is present. This loss of height leads to altered jaw mechanics with significant deviation toward the fractured side or, in the case of bilateral fractures, open bite deformity. The derived malocclusion is difficult to treat later with prosthesis. Bilateral condylar fractures is an area where treatment is more controversial. Ellis has found that 10% of patients in this cohort do not respond well to closed treatment. Unfortunately, which patients are recalcitrant to closed treatment is unclear. Some investigators have argued that significantly severe dislocation of the fractured condyle is an indication for open reduction and internal fixation.<sup>5</sup> Studies have shown this not to be the case and that, through remodeling, appropriate occlusion can be re-established despite the visible alteration in jaw mechanics.<sup>4</sup>

## **TREATMENT GOALS AND PLANNED OUTCOMES**

The principal goal of treatment is re-establishment of normal occlusion and mastication.<sup>1</sup> Beyond this, restoration of baseline jaw mechanics and overall cosmesis are also given consideration. As discussed previously, the ideal surgical technique to obtain these goals is variable and based on individual injury while weighing the risk/benefit of surgery.

## **PREOPERATIVE PLANNING AND PREPARATION**

As with any other surgery, patient safety is of penultimate importance. Patient stability before surgery must be assessed with associated preoperative evaluation and laboratory work. Comorbid injuries are not unusual and need to be assessed in regards to urgency and triage of treatment. A surgical plan must be determined. Patients require adequate dentition or at least intact dentures to even consider closed reduction or mandibular–maxillary fixation. If endoscopic reduction is planned, appropriate equipment is necessary that may not be readily available.<sup>6</sup> With external approaches, obtaining cervical spine clearance and removal of cervical collar allows the head to be turned, making surgery significantly easier.

## **PATIENT POSITIONING**

With either an open or closed approach, it is likely patients are placed in maxillary–mandibular fixation, if only intraoperatively. Therefore, nasotracheal intubation is used in most cases, with the circuit brought up over the head and secured with a head wrap. In cases where this is not a possibility, due to comorbid injuries or need

for long-term ventilator support, then a tracheostomy must be considered. Regardless of treatment planned, the arms are tucked and the table is turned 180° to allow several surgeons and assistants access to the head.

## PROCEDURAL APPROACHES

### *Pediatric Condylar Fractures*

---

Condylar fractures are the most common pediatric mandibular fracture and present bilaterally in 20% of cases.<sup>7</sup> Prior to age 6, most fractures are intracapsular, whereas after that age they occur most frequently in the neck of the mandible. When normal occlusion is present, fractures of the condylar region are treated conservatively with close observation, soft diet, and pain medication. When there is malocclusion, a short course of maxillary–mandibular fixation is warranted. Limiting fixation to 7 to 10 days helps limit the chance of joint ankylosis, although postoperative physiotherapy may still be beneficial. Choice of technique is largely dependent on the age of the child and, more importantly, the quality and quantity of dentition. When possible, intradental wires with arch bars maybe placed. If not possible, intermaxillary fixation using 1-point circummandibular wiring should be used, attaching it to a wire wrapped around a hole drilled through piriform aperture. Due to the possibility of injuring nonerupted teeth, intermaxillary fixation screws should not be placed. It is important to discuss chin deviation during chewing and the possibility of long-term growth abnormalities of the jaw with patients' parents.

### *Closed Reduction*

---

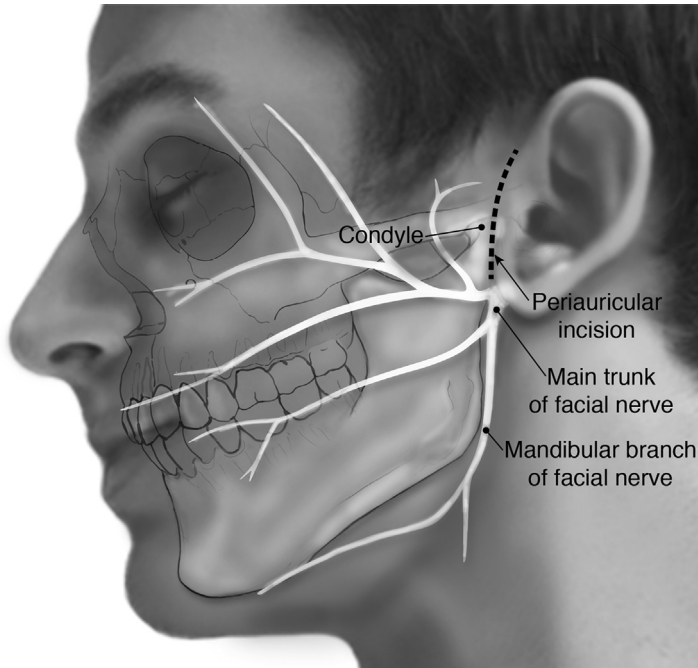
Several approaches for closed reduction may be used. The authors have found that obtaining occlusion with elastic bands offers the same benefit as metal wiring but permits patients to subtly shift into natural occlusion while mobilizing earlier, which improves dietary intake and lowers the chance of joint ankylosis. If there are concerns about patient compliance with elastics, surgeons may elect to stay with the reliability of complete wire fixation.

### *Preauricular Approach*

---

The preauricular approach is excellent to expose the temporomandibular joint (TMJ) and to remove displaced condylar fragments. The incision also hides well in the preauricular crease. It provides, however, poor exposure and visualization of the subcondylar region. If placing a fixation plate and screws is desired, it often requires inferior retraction on the facial nerve, potentially causing paresis (**Fig. 1**).

The incision is marked in a skin crease in front of the pinna beginning at the superior pole of the helix and extending inferiorly to the inferior anterior edge of the tragus. The incision is carried through skin and subcutaneous tissues. Superior to the zygomatic arch, the temporoparietal fascia is incised to reach the superficial layer of the deep temporal fascia, with care taken to avoid damaging the superficial temporal vessels and auriculotemporal nerve. Inferior to the zygomatic arch, the dissection precedes to the same depth as the superior dissection, immediately anterior to the tragal cartilage. In the superior portion of the incision, the superficial layer of the deep temporal fascia is then incised starting at the anterior superior portion of the incision and running at a 30° angle to the long axis of the helix, toward the tragus. This exposes a layer of fat between the superficial and deep layers of the deep temporal fascia, and a periosteal elevator can be inserted in this incision deep to the superficial layer of the deep temporal fascia. The periosteal elevator can be used to free the periosteum off of the lateral zygomatic arch and create a tunnel inferior to the zygomatic arch. The



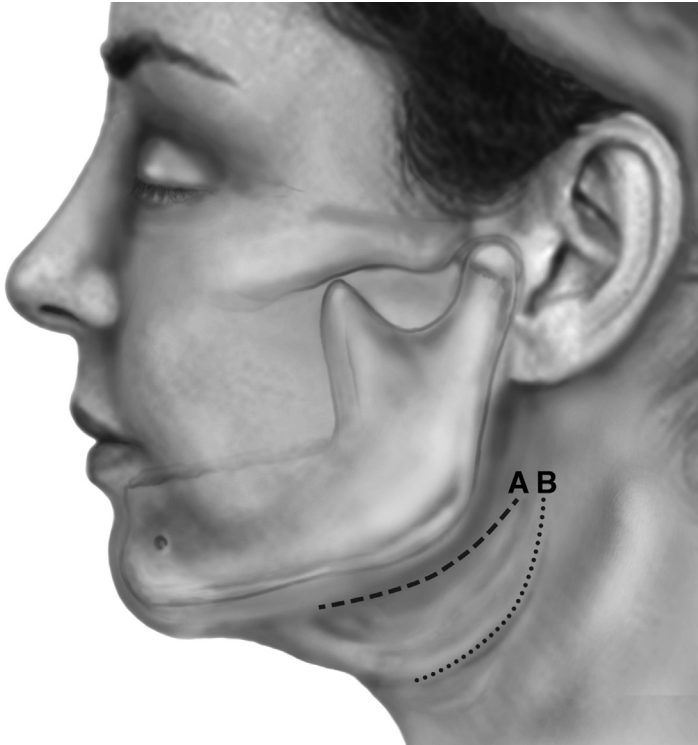
**Fig. 1.** The dashed line represents the incision for the preauricular approach. The relationship between the incision, the condyle, and the facial nerve is seen.

intervening tissue can then sharply be divided posteriorly along the original axis of the vertical skin incision. This subperiosteal flap can then be reflected anteriorly from the root of the zygomatic arch, thus protecting the temporal branch of the facial nerve. Dissection proceeds anteriorly until the articular eminence and entire TMJ capsule should be revealed. To help locate and palpate this, the mandible can be opened and closed. Dissection and retraction can proceed inferiorly to reveal the subcondylar region.<sup>8-11</sup>

### ***Submandibular/Risdon Approach***

The submandibular/Risdon approach provides good access to the ramus and lower subcondylar areas of the mandible but can be somewhat limited for high subcondylar or condylar fractures because the incision is positioned a long ways away from these fractures. The main complication is either paralysis or paresis of the marginal mandibular branch of the facial nerve either from direct injury or from retraction forces. The scar created is also visible on the neck.

The 4-cm to 5-cm incision is marked 1 to 2 fingerbreadths below the inferior border of the mandible near the angle (**Fig. 2**). Care should be taken to hide the incision within a skin crease if possible. The dissection proceeds through skin and subcutaneous tissue until the superoinferiorly oriented fibers of the platysma muscle are identified. The platysma is divided to reveal the superficial layer of the deep cervical fascia, the submandibular gland in the anterior aspect of the incision, and often the facial artery and vein. The marginal mandibular branch of the facial nerve is located within or just deep to the superficial layer of the deep cervical fascia and sometimes are encountered running inferior to the border of the mandible, so care should be taken to preserve



**Fig. 2.** The incision for the submandibular approach is made 1–2 fingerbreadths below the mandible. Line A shows an incision paralleling the mandible, whereas line B shows an incision made along a skin crease. Placing the incision in a skin crease often improves cosmesis.

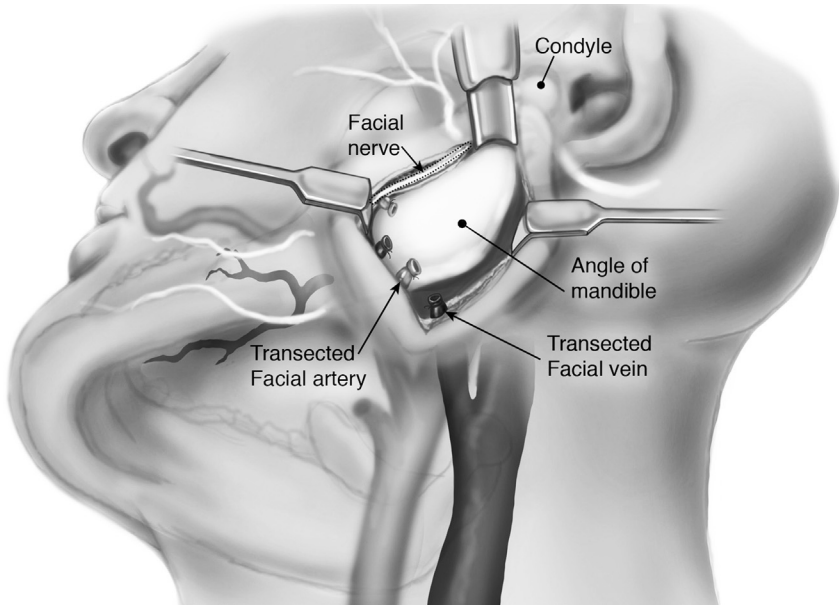
it. This can be done by identifying it directly, by only dividing tissue that has been dissected to reveal no nerve, by incising the fascia covering the submandibular gland at its inferior border and elevating it superiorly, or by ligating the facial vein and retracting this superiorly as the marginal mandibular branch is superficial to the facial vein (**Fig. 3**). In many instances, however, the nerve is superior to the area of dissection and is not encountered.

Dissection continues through the deep cervical fascia until the inferior border of the mandible is covered only by periosteum anterior to the premasseteric notch or by the pterogomasseteric sling posterior to the notch. The periosteum or pterogomasseteric sling is divided sharply down to bone and subperiosteal dissection is performed until the fracture site is completely exposed.<sup>3,9,11–13</sup>

### ***Retromandibular Approach***

The retromandibular approach provides direct access to the entire posterior ramus and condylar neck and the incision is located proximal to these sites. Potential negatives of this approach include injury to branches of the facial nerve, a visible scar, and potential for a salivary fistula.

There are 2 different retromandibular approaches and the skin incision is marked differently for each one. If a retroparotid approach is desired, then the skin is marked 2 cm posterior to the posterior border of the ramus of the mandible. After incision, the parotid gland is separated from the sternocleidomastoid muscle and then can be



**Fig. 3.** Seen is the submandibular approach after ligation and retraction of the facial vessels. The pterygomasseteric sling has been elevated off to expose the mandible.

retracted superiorly. The retroparotid approach theoretically has an advantage of protecting the branches of the facial nerve within the parotid gland but negates the advantage of being closer to the ramus and subcondylar regions of the mandible. If a transparotid approach is desired, then the incision is made immediately posterior to the ramus approximately 0.5 cm inferior to the lobule and continues inferiorly for approximately 3 cm to the angle of the mandible. The scant platysma muscle and parotid capsule are then sharply incised. Blunt dissection in an anteromedial direction commences toward the posterior border of the mandible, with all spreads made parallel to the course of the facial nerve branches. Frequently the cervical, marginal mandibular, or buccal branches of the facial nerve are encountered and, if necessary for exposure of the fracture, these branches can be dissected free of tissue for a couple of centimeters and then gently retracted. The pterygomasseteric sling at the posterior border of the mandible is exposed and is incised sharply down to the bone. Subperiosteal dissection with stripping the masseter muscle off of the ramus is then performed to expose the fracture site. Surgeons should always be mindful of the retromandibular vein that runs vertically across the dissection site.<sup>3,9,11</sup>

### ***Intraoral Approach***

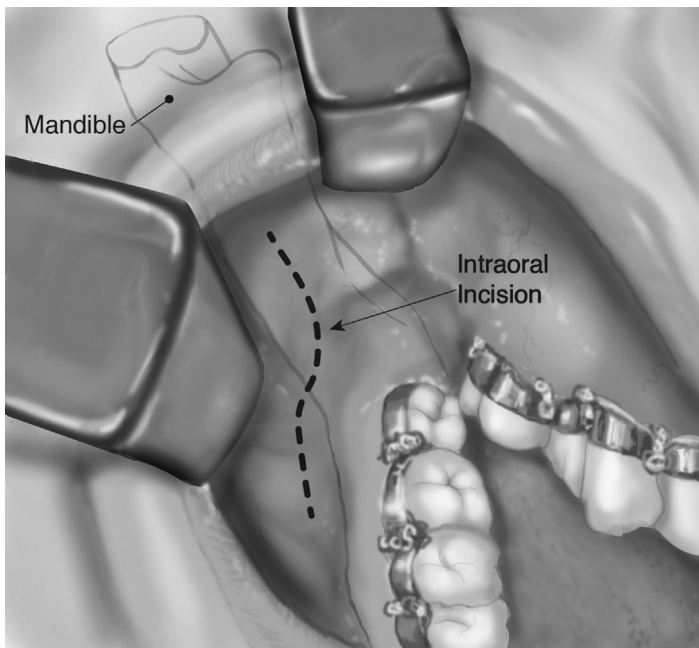
The traditional intraoral approach often provides poor visualization of the posterior border of the ramus and subcondylar region and it can be difficult to apply fixation plates and screws. Many types of retractors, including lighted retractors, and trocar systems have been developed to help aid in the traditional intraoral approach. Some investigators have also advocated fixing subcondylar fractures with a lag screw, which is easier to apply than plates and screws through the exposure provided by the intraoral approach.<sup>14</sup> The main advantages of the intraoral route are that there are no external incisions or visible scars and that the branches of the facial nerve are not placed at risk.

An incision is made in the ipsilateral gingivobuccal sulcus, preserving a cuff of mucosa medially to facilitate closure. This should start around the second molar and extend posteriorly over the external oblique ridge and further extension along the anterior border of the ramus (Fig. 4). The periosteum is incised and a mucoperiosteal flap is raised and reflected to expose the anterior and lateral part of the ramus. Subperiosteal dissection up the anterior edge of the ascending ramus strips the buccinator attachments, which allows the muscle to retract upward, minimizing the chance of herniation of the buccal fat pad. The masseter muscle is stripped off of the lateral surface of the ramus as dissection proceeds superiorly, exposing the condylar neck and sigmoid notch.<sup>9,14</sup>

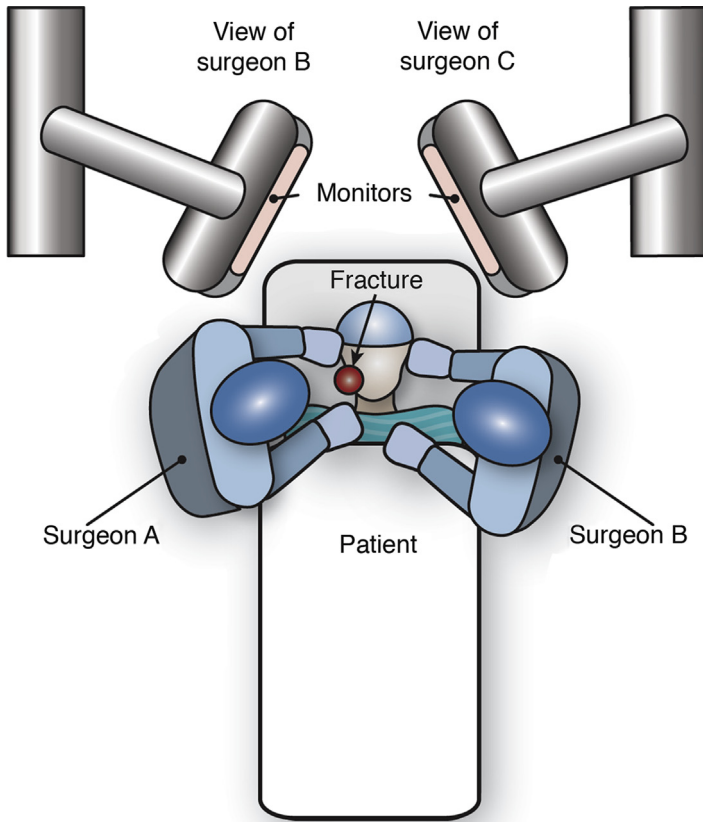
### **Endoscopic Approach**

The endoscopic approach is the authors' preferred method open treatment for condylar fractures (Fig. 5). Arch bars are applied and all other mandibular fractures are treated. A vertical incision is made along the anterior border of the ascending ramus of the mandible. Next, subperiosteal dissection is performed widely, including dissection around the posterior edge of the mandible. This improves mobilization of the fractured segment.

Using a preoperative Panorex, the degree of overlap of the proximal segment on the distal mandible is estimated and a sterile silastic block wedge is cut to this vertical dimension. Patients are placed in heavy elastics across the entire occlusal plane except on the ipsilateral molar region, where this block is wedged while the distal segment is distracted inferiorly. At this point, the adequacy of the reduction is judged with a standard 30° endoscope with irrigating sheath. The authors have found the



**Fig. 4.** Seen is the incision for the intraoral approach on the right side. This should start lateral to the posterior inferior molars, leaving a cuff of tissue medially to sew to and then extend up onto the ascending ramus of the mandible.



**Fig. 5.** Schematic view showing 2 surgeons' approach to endoscopic approach. Video towers should be placed behind and adjacent to each surgeon to allow both surgeons to comfortably see.

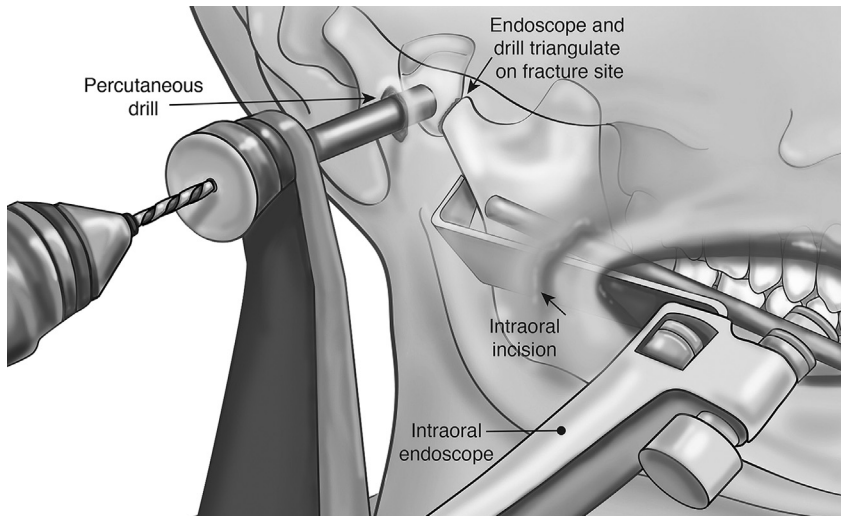
sheaths used for endobrow lifts invaluable in regards to both irrigation and for tenting up surrounding tissue and improving visualization. Generally, the fracture is well reduced or easily reducible at this juncture. If there is still some overlap present, the silastic block wedge is resized.

Next, the fracture is plated with a 2.0-mm mini-locking screw plate, with 2 screws on either side of the fracture line. Screws are placed through a single transcutaneous stab incision (**Fig. 6**). The screws are placed first on either side of the fracture line with the proximal segment screwed first. The occlusion is verified, and then the outside screws placed. The intraoral incision is closed with a single running layer of 3.0 Vicryl suture. Postoperatively, the patients are mobilized with physiotherapy exercises as soon after fracture fixation as their other injuries allow. Patients are maintained on a no-chew diet for a period of 6 weeks.<sup>6</sup>

### COMPLICATIONS IN CONDYLAR FRACTURES

Complications of condylar/subcondylar fractures can be secondary to the original injury as a result of treatment of the fracture or from failure to treat the fracture. These





**Fig. 6.** Endoscopic view showing percutaneous incision with camera in place for direct observation.

complications can be either immediate or long term. Immediate complications include pain, swelling, bleeding, bruising, trismus, nerve damage, loss or damage of teeth or bone, and airway compromise. Airway compromise can be caused from swelling, mandibular displacement, foreign body aspiration, or bleeding, which can be treated with steroids, an oropharyngeal or nasopharyngeal airway, preliminary reduction and immobilization in severely displaced fractures, intubation, or tracheostomy. Also, with the force required to fracture the mandible, it is possible to have other body system injuries that take priority over the mandible fracture, and these should be ruled out with history, physical examination, and other studies, if indicated.<sup>9,15</sup> An immediate complication seen during surgical treatment can be nerve damage. Facial nerve damage is more common in the external approaches used to access the condylar region, such as the preauricular, retromandibular, or submandibular approaches, than in the intraoral approach. Damage to the inferior alveolar nerve can also occur from screw placement into the nerve in the mandibular canal.<sup>15,16</sup>

Long-term complications can result either from a surgical procedure to treat the fracture or from patients not receiving proper treatment. Long-term complications specific to open procedures to reduce and fixate subcondylar fractures include unsightly scars and parotid fistula.<sup>15</sup> The most common long-term complication is infection. Infections involving condyle or subcondylar fractures seem to occur less frequently than other locations of the mandible.<sup>17,18</sup> Some studies have shown that infection rates are higher in open reduction than closed reduction procedures.<sup>18</sup> Risks of developing an infection include delay in treatment, the lack or inappropriate use of antibiotics, teeth in the fracture line, comminution of the fracture, patient noncompliance, inadequate reduction, and concurrent medical problems that inhibit wound healing.<sup>15</sup> Most infections are of minor consequence and can be treated with antibiotics. They do, however, have the potential to develop into more significant sequelae, such as abscess, wound dehiscence, debilitating pain, loose hardware, malunion, nonunion, chronic osteomyelitis, and acquired skeletal deformities.<sup>18</sup> Abscess should be treated with incision and drainage. Hardware might need to be removed and replaced in instances of infection that does not respond to antibiotics

or drainage. Osteomyelitis is treated by means of a multistep approach involving incision and drainage, sequestrectomy, frequent irrigations, immobilization, and prolonged antibiotics. In cases of malunion, nonunion, or osteomyelitis nonresponsive to treatments (listed previously) or when bone volume is lost, reconstructive surgery with bone grafting or microvascular surgery may be necessary.<sup>9,15,16</sup>

Another long-term complication is nonunion, which is the lack of an osseous union of 2 or more fractured bone segments after the usual 6-week to 8-week healing period. This can be treated first by conservative management, which consists of prolonged immobilization and optimizing concomitant medical conditions or infections. If this fails, then a second surgical intervention is indicated, which could involve removing soft tissue or teeth that are preventing bone-to-bone contact, removing any infected tissue or bone, and then re-establishing occlusion, reduction, and rigid fixation. Bone grafts might be needed if there is not enough vascularized bone on both sides of the fracture that can be reduced to achieve bone-to-bone contact.<sup>15,17</sup>

Malunion can occur when fractured segments achieve bony union in a less than ideal position because they are not properly reduced or fixated. Because of their anatomic location, malunion of condylar and subcondylar fractures can lead to malocclusion, TMJ arthropathy, decreased lateral excursion, degenerative joint disease, ankylosis, mandibular deviation, and potential growth disturbances.<sup>9,15,16</sup> When malunion is recognized, it should be treated as quickly as possible. Minor malocclusion or malunion can be treated with arch bars, elastic bands, or orthodontic care. More gross abnormalities may require surgery with osteotomies, proper reduction, and re-establishment of proper occlusion.<sup>15</sup>

Other long-term complications include ankylosis, growth disturbance, and condyle resorption. Ankylosis, or fusion of the condyle to the articular fossa, can occur with or without surgery and is more common in the pediatric population. It is generally associated with fractures of the condylar process rather than the subcondylar areas. It can best be avoided by physical therapy regimens initiated as soon as possible and by avoiding long periods of immobilization. Should ankylosis occur, secondary surgical techniques need to be used.<sup>9,16</sup> Because the condyle serves as a growth center for the mandible, a fracture in this area can cause growth disturbance in younger patients, resulting in asymmetry or retrognathia.<sup>9</sup> Condylar resorption, in which the condyle changes shape and decreases in size, can be caused by excessive dissection and injury of the adjacent blood vessels during surgery; it be minimized by careful surgical technique.<sup>16</sup>

## POSTPROCEDURAL CARE

Postoperatively, patients are given pain medication and started on Peridex rinse after each meal for 3 days. The authors often also prescribe a short course of an antiemetic and stool softener, to ameliorate the most common postsurgical issues. If the jaw is wired shut, disposable wire cutters are sent home with patients, in case of emesis. A liquid or no-chew diet is also implemented for up to 6 weeks. It is important to counsel patients and families in regards to typical weight loss associated with closed reduction and the necessity to supplement routine dietary intake. Risks of postoperative smoking and poor wound healing are also reviewed.

## REHABILITATION AND RECOVERY

Patients are routinely maintained on a no-chew diet for 6 weeks. If elastic bands are used in closed reduction, then immediate mobilization is encouraged, with slowly increasing jaw mobility and opening. Elastic bands are continued for 3 weeks and

with a further 3 weeks of arch bars maintenance before their removal. If instead, wires are used, these are kept in place 2 to 3 weeks and then replaced with elastics and again mobilization is highly encouraged, following the same time course. If there are concerns of continued limited joint mobility, then physiotherapy may be prescribed.

## OUTCOMES AND CLINICAL RESULTS IN THE LITERATURE

Debate continues regarding optimal treatment of condylar fractures. Regardless of approach, early mobilization is key to long-term prognosis.<sup>19</sup> Pediatric cases are best treated conservatively. In a review article, Nussbaum and Laskin<sup>20</sup> attempted to more definitively answer whether open or closed is the best approach. Unfortunately, due to significant inconsistencies in measured variables, the investigators were unable to come up with a conclusion. Surgeons are left on their own to interpret the available data and using personal experience to determine the best treatment for our patients.

## SUMMARY

There is a role for both open and closed reduction in the treatment of condylar fractures. Using a thoughtful approach with an understanding of the pros and cons of each treatment option, applied individually to each patient fracture, leads to the best long-term outcomes while minimizing the sequelae associated with surgery. Careful unbiased critique of postoperative results with the goal of continually improving techniques and outcomes is, in the end, significantly beneficial to both patients and surgeons.

## REFERENCES

1. Ellis E III, Throckmorton G. Treatment of mandibular condylar process fractures: biological considerations. *J Oral Maxillofac Surg* 2005;63:115–34.
2. Malkin M, Kresberg H, Mandel L. Submandibular approach for open reduction of condylar fractures. *Oral Surg Oral Med Oral Pathol* 1964;17:152.
3. Landes C, Lipphardt R. Prospective evaluation of a pragmatic treatment rationale: open reduction and internal fixation of displaced and dislocated condyle and condylar head fractures and closed reduction of non-displaced, non-dislocated fractures. Part I: condyle and subcondylar fractures. *Int J Oral Maxillofac Surg* 2005;34:859–70.
4. Ellis E III, Kellman RM, Vural E. Subcondylar fractures. *Facial Plast Surg Clin North Am* 2012;20:365–82.
5. Mathes SJ, Hentz VR. *Plastic surgery*. 2nd edition. Philadelphia: Saunders Elsevier; 2006.
6. Ducic Y. Endoscopic treatment of subcondylar fractures. *Laryngoscope* 2008; 118:1164–7.
7. Cole P, Kaufman Y, Hollier L. Managing the pediatric facial fracture. *Cranio-maxillofac Trauma Reconstr* 2009;2(2):77–83.
8. He D, Yang C, Chen M, et al. Modified preauricular approach and rigid fixation for intracapsular condyle fracture of the mandible. *J Oral Maxillofac Surg* 2010;68(7): 1578–84.
9. Montazem AH, Anastassov GA. Management of condylar fractures. *Atlas Oral Maxillofac Surg Clin North Am* 2009;17:55–69.
10. Ellis E III, Zide MF. Chapter 12 Preauricular approach. *Approaches to the facial skeleton*. Lippincott Williams & Wilkins; 2006. p. 193–212.

11. Ebenezer V, Ranalingam B. Comparison of approaches for the rigid fixation of subcondylar fractures. *J Maxillofac Oral Surg* 2011;10(1):38–44.
12. Kanno T, Mitsugi M, Sukegawa S, et al. Submandibular approach through the submandibular gland fascia for treating mandibular fractures without identifying the facial nerve. *J Trauma* 2010;68(3):641–3.
13. Ellis E III, Zide MF. Chapter 9 Submandibular approach. *Approaches to the facial skeleton*. 2nd edition. Lippincott Williams & Wilkins; 2006. p. 153–68.
14. Patil RS, Gudi SS. Management of subcondylar fracture through intraoral approach with rigid internal fixation. *J Maxillofac Oral Surg* 2011;10(3):209–15.
15. Zweig BE. Complications of mandibular fractures. *Atlas Oral Maxillofac Surg Clin North Am* 2009;17:93–101.
16. Choi KY, Yang JD, Chung HY, et al. Current concepts in the mandibular condyle fracture management part I: overview of condylar fracture. *Arch Plast Surg* 2012; 39:291–300.
17. Stacey DH, Doyle JF, Mount DL, et al. Management of mandible fractures. *Plast Reconstr Surg* 2006;117(3):48e–60e.
18. Lamphier J, Ziccardi V, Ruvo A, et al. Complications of mandibular fractures in an urban teaching center. *J Oral Maxillofac Surg* 2003;61:745–9.
19. Zachariades N, Meztis M. Fractures of the mandibular condyle: a review of 466 cases. Literature review, reflections on treatment and proposals. *J Craniomaxillofac Surg* 2006;34(7):421–32.
20. Nussbaum M, Laskin D. Closed versus open reduction of mandibular condylar fractures in adults: a meta-analysis. *J Oral Maxillofac Surg* 2008;66:1087–92.