

Fat Grafting in Trauma and Reconstructive Surgery

Yadranko Ducic, MD, FRCS(C), FACS^{a,b,c,d}

KEYWORDS

• Fat grafting • Lipotransfer • Reconstructive surgery

The Greeks long ago recognized the ideals of proportion and beauty, attempting to reduce it to a mathematical formula (“the golden mean”) that could be equally well applied to architecture, art, music, and general aesthetics.¹ Da Vinci and Renaissance artists attempted to solve the interrelationships of various parts of the human form and with it, define what determined beauty. Modern ideals of beauty have evolved from sharp, bold, dramatic features to softer and more subtle soft tissue envelopes covering an adequately voluminous and symmetric underlying osseous structure. The midface of youth is a full, vertically well-supported structure. Aging brings deflation of the midface associated with vertical descent. Reversal of this volume loss with fat grafting or other fillers has become a major recognized goal of aesthetic surgeons today. Fat grafting in reconstructive surgery is not a new concept. Neuber² was the first to transplant fat for reconstructive purposes, harvesting pearls of fat from the arm to fill a facial defect. Czerny,³ in 1895, transplanted a lipoma from the back to a breast for augmentation. Certainly fat does fulfill many of the features of an ideal filler by being biocompatible, inexpensive, persistent, and available in large quantities, and by having no risk for rejection and a low chance of infection. However, the long-term retention of transplanted adipocytes has been debated, and has been a polarizing issue in the plastic surgery community, with various surgeons either embracing lipotransfer wholeheartedly or rejecting it as completely ineffective. Thus, it is not surprising that a dramatic

range of 20% to 90% for resorption of transplanted fat has been reported.^{4–7}

GENERAL CONSIDERATIONS

Harvesting and Graft Preparation Technique and Effects on Graft Retention

Commonly used techniques for fat harvest include suction machine–assisted harvest (often as a welcome byproduct of liposuction) or hand-assisted syringe aspiration. Although the latter technique would seem less traumatic on aspirated adipocytes because of less mechanical disruption, Smith and colleagues⁸ noted no difference in graft survival between techniques.

In addition, several authors promote washing harvested fat in physiologic solutions before implanting to help adipocyte survival.^{9,10} Lactated Ringer’s solution and 0.9% normal saline are commonly used for this purpose. However, laboratory studies showed no evidence of benefit from this step.⁸ In fact, prolonged exposure to air and the increased manipulation of washing may result in loss of adipocyte viability from oxidization.

Centrifugation

Centrifuging the fat graft separates it into three distinct layers. The bottom or serous fluid layer is composed primarily of injected local anesthetic, tumescent solution, and serous fluid. Injecting this layer causes temporary same-day augmentation from the low yield of adipocytes. The top or free fatty acid layer is composed of inflammation-promoting triglycerides that may lead to

^a Otolaryngology and Facial Plastic Surgery Associates, Fort Worth, TX, USA

^b Department of Otolaryngology, University of Texas Southwestern Medical Center, Dallas, TX, USA

^c Baylor Neuroscience Skull Base Program, Dallas, TX, USA

^d Otolaryngology and Facial Plastic Surgery, JPS Health Network, Fort Worth, TX, USA

E-mail address: yducic@sbcglobal.net

increased delayed resorption of transplanted fat from mobilization of an increased inflammatory cascade. The middle or fat layer is what is generally transplanted during this process. It is composed of the highest concentration of viable fat cells (Figs. 1 and 2). The author prefers using centrifugation with minimal exposure of the fat to air or manipulation as outlined below.

How Much to Inject?

Several consideration must be taken into account when performing lipotransfer. If centrifugation is not used, a variable and, in the author's experience, unpredictable amount of transplanted fat will consist of serous fluid, tumescent solution, and local anesthetic, none of which results in long-term volume augmentation. In addition, some transplanted fat will not survive because of mechanical trauma, prolonged exposure to air, or failure of the recipient bed to provide an adequate blood supply. A history of local trauma, radiation, or extirpative surgery can all result in decreased recipient supply in patients undergoing reconstructive surgery.¹¹

Finally, recipient bed trauma from injecting the fat graft through a cannula causes edema and a sustained inflammatory response, which can obscure visual clues about the adequacy of the filling. The author does not inject local anesthetic into the recipient bed except for nerve blocks in patients undergoing surgery with sedation. He also prefers to minimize the passes into the defect to be filled and gently massage the multiple small fat grafts into a smooth contour rather than perform hundreds of passes to minimize swelling and the magnitude of the delayed and prolonged inflammatory response that may result in increased graft resorption. Placing a smaller number of fat packets in proximity allows increased surface area contact with the surrounding tissues and decreased trauma from placing large fat grafts

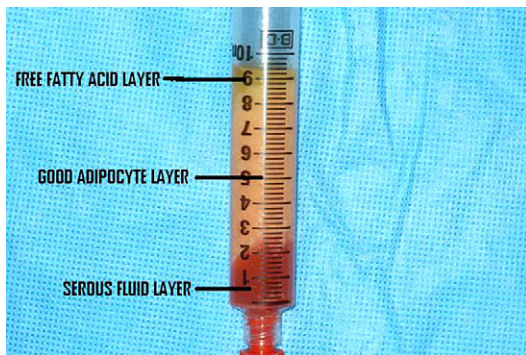


Fig. 1. Clear distinction between the three layers of harvested fat after centrifugation.

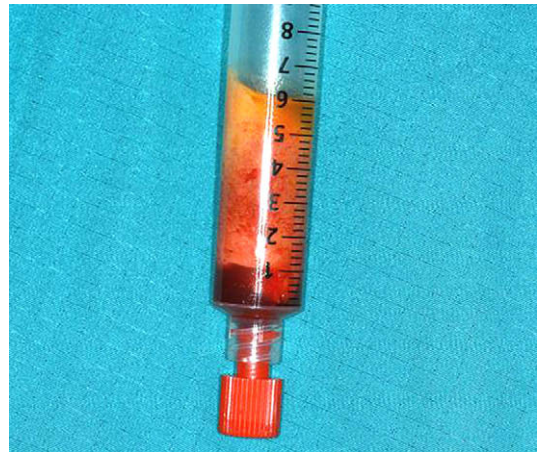

Fig. 2. General appearance of harvested fat without centrifugation. Note: no crisp, defined point is present between each of the layers, as noted in Fig. 1.

and massaging vigorously over a large area (to be discouraged) or placing miniscule grafts over hundreds of passes (to be discouraged).

Added Benefits of Fat Transfer

Surgeons are beginning to recognize that transplanted fat cells have significant beneficial effects on surrounding tissues that extend beyond simple volume improvement. Coleman¹² noted improvement in quality of aging skin, overlying scars, and radiation damage. These benefits may be related to the presence of preadipocytes and adipose-derived stem cells that have a certain undefined and somewhat unpredictable ability to repair damaged tissue. This effect may have tremendous benefit in reconstructive surgery, because the contracted, scarred recipient bed often requires more than volume to improve appearance (Figs. 3 and 4).

Fat Graft Retains Memory

Transplanted adipocytes retain some originating site characteristics even when placed elsewhere in the body. If a patient tends to gain weight along the lower abdominal wall and thighs, and this is the source of the fat graft, the transplanted fat that has taken can be expected to increase in volume if the patient gains significant weight at the donor site. This occurrence may be challenging in reconstructive cases, in which large amounts of fat are often selectively deposited on one side of the face only, as opposed to both sides being symmetrically augmented, as in cosmetic surgery. Therefore, patients undergoing reconstruction should be cautioned about large fluctuations in weight, because this may deleteriously affect their final aesthetic outcome.

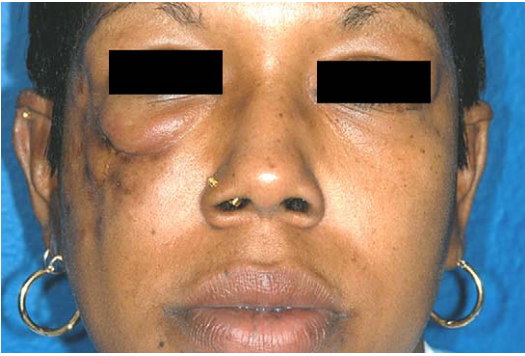

Fig. 3. Preoperative appearance of a woman who had undergone a direct transfacial approach to an orbital floor fracture. She developed a tremendous amount of scarring in the entire right cheek with contraction, adherence to the underlying bone, subcutaneous tissue atrophy, and hyperpigmentation in the overlying skin that was not remedied with bleaching agents or passage of time.

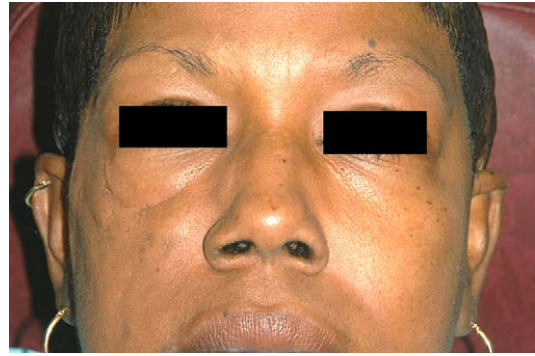

Fig. 4. Postoperative appearance of patient in Fig. 3 after releasing underlying contracture with second-stage lipotransfer. Improvement occurred in the volume of the right cheek. In addition, note the significant favorable changes in quality and color of the overlying skin after lipotransfer to the underlying tissue.

PERSONAL TECHNIQUE OF FAT GRAFTING

After adequate Betadine (or other equivalent agent) preparation of the donor and recipient sites, a stab incision is made within the umbilicus to allow for a hidden donor scar. Next, tumescent solution (composed of 500 mL lactated Ringer's solution, 20 mL 2% plain lidocaine, 1 mL epinephrine 1:1000, and 1 mL 3% sodium bicarbonate) is injected symmetrically into the lower abdominal wall quadrants into the deep subcutaneous tissue plane. Graft harvest should be initiated after approximately 10 minutes to allow for adequate local anesthetic effect to occur.

Dry tunneling is then performed with the liposuction cannula. No negative pressure is applied at this point in the procedure. The tunneling encompasses the entire area of proposed graft harvest and facilitates less-traumatic adipocyte acquisition. Liposuction cannulas (3–5 mm) attached to a syringe are used to harvest the fat symmetrically from the deep subcutaneous tissue. More superficial harvest may result in increased bruising, more fibrous fat, and surface irregularities, and should be avoided. The donor site is closed with resorbable suture, antibiotic ointment is applied to the umbilicus, and an abdominal binder is worn by the patient for 2 to 4 weeks, depending on the volume of fat harvested. The binder will minimize swelling, maximize comfort, and allow for nice smooth, controlled adaptation of the (liposuction) elevated pockets of subcutaneous tissue to the underlying fascia.

The fat is then centrifuged at 3000 rpm for 3 minutes. The fat graft is decanted, efficiently

and completely removing the serous fluid (composed primarily of blood and tumescent solution) and free fatty acid layers (oily layer superficial to the “good fat”). Injecting the serous layer material causes false augmentation that disappears in 24 to 48 hours, whereas injecting the free fatty acid layer incites a delayed and prolonged inflammatory response that expedites graft resorption.

Alternatively, the syringe may be allowed to stand upright for 15 to 20 minutes to allow these layers to settle, but this is neither as efficient or clean as centrifugation in the author's experience. Next, the fat graft is injected into aesthetically hidden areas using an injection gun (Fig. 5) that delivers metered doses (excellent for resident teaching and supervision) or using free-hand technique wherein the injection needle is attached directly to the syringe.

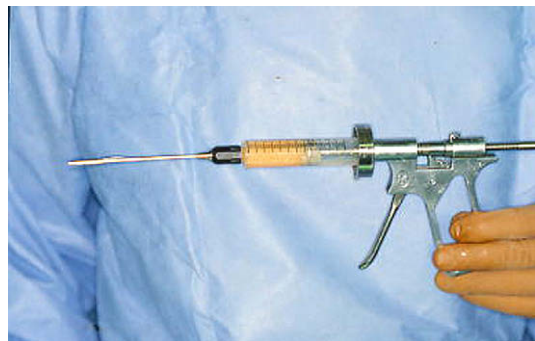

Fig. 5. Injection gun will deliver metered doses with each pull of the trigger. This technique is somewhat less efficient than free-hand technique but more controlled in inexperienced hands.

Access stab incisions for fat injection are cheeks (intranasal), lips/perioral region (oral commissure), periorbital (gingivobuccal or preauricular), and forehead (hairline). The author does not favor the Coleman technique, involving hundreds of tiny passes crisscrossing each other in multiple layers, because he believes it results in an inordinate amount of surgical trauma, leading to excessive and prolonged postoperative edema that ultimately results in unpredictable graft retention. The author prefers to inject somewhat larger volumes along the path of the injection needle's withdrawal, because he finds it allows a more controlled and smoother deposit of fat.

The author does not overcorrect, because he has treated many patients who have retained all of the fat without resorption of any sort. The author overcorrected a few patients when first using the technique, assuming resorption would occur to some degree. However, he was unpleasantly surprised when no resorption occurred, and this small group of patients had to undergo further procedures to correct the overcorrection. Once the fat is injected, the author gently massages the surrounding tissue through a gauze (to minimize direct and overly aggressive pressure on the fat graft).

When using fat grafting techniques in posttraumatic or reconstructive surgery cases, the outlined technique of harvest is unchanged. The fat should be harvested immediately before implantation rather than remaining for prolonged periods on a side table. This technique minimizes exposure to air, which may cause oxidization. The interval between harvest and exposure to nourishing serous fluids should be decreased at the recipient site.

If simple loss of volume occurs, without much scar tissue formation at the recipient site, injection will be similar to that in aesthetic cases. When significant scarring is present, preinjection tunneling with a blunt-tip 2-mm injection cannula into the area of proposed augmentation is beneficial (**Fig. 6**). In cases of severe scar contracture to underlying tissue, a V-dissector (**Fig. 7**) is used to release the area of tethering before dry tunneling the remainder of the area with a blunt-tipped cannula. Excessive release with the V-dissector results in an excessively large pocket into which the injected fat will be deposited. Such a large volume of fat has an increased risk for resorption because it will be too far away from (an inadequate scarred field) blood supply.

The fat then should be injected within the deep subcutaneous tissue, approaching the underlying bone in some cases. This procedure results in the most aesthetically favorable augmentation

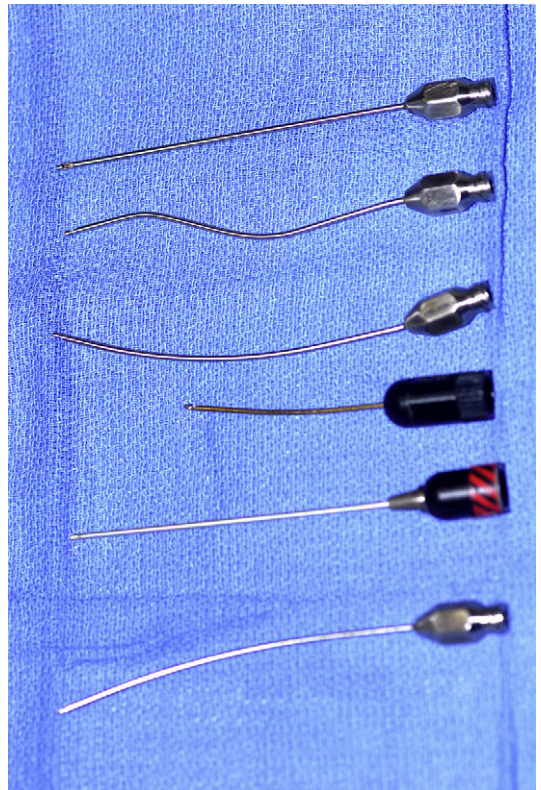


Fig. 6. Various injection cannulas of differing sizes and curvatures are required to facilitate access to the recipient site through hidden injection sites.

in patients who have posttraumatic scars. If the surgeon notes that excessive scarring is present, of which entire release would result in a large pocket, the tethered area should be completely released and the patient returned to the operating room in 4 to 6 weeks for lipotransfer. If the surgery is performed under general anesthesia, no local anesthesia is administered at the recipient site. If the procedure is performed under sedation, then nerve blocks with limited amounts of anesthetic are injected. This technique causes less distortion of the recipient bed tissues and minimizes interruption of blood flow to the grafts once implanted. The author prefers to use general anesthesia for patients who have posttraumatic scars.

Patients are instructed to avoid any manipulation of the grafted areas for 2 weeks other than bathing. Edema and bruising are generally mild except in the lips and lower eyelid areas, where prolonged edema lasting 2 to 3 weeks may be noted.

The author generally uses a preoperative first-generation cephalosporin and metronidazole and a single dose of intravenous dexamethasone. Postoperative oral first-generation cephalosporins are provided for 1 week postoperatively.

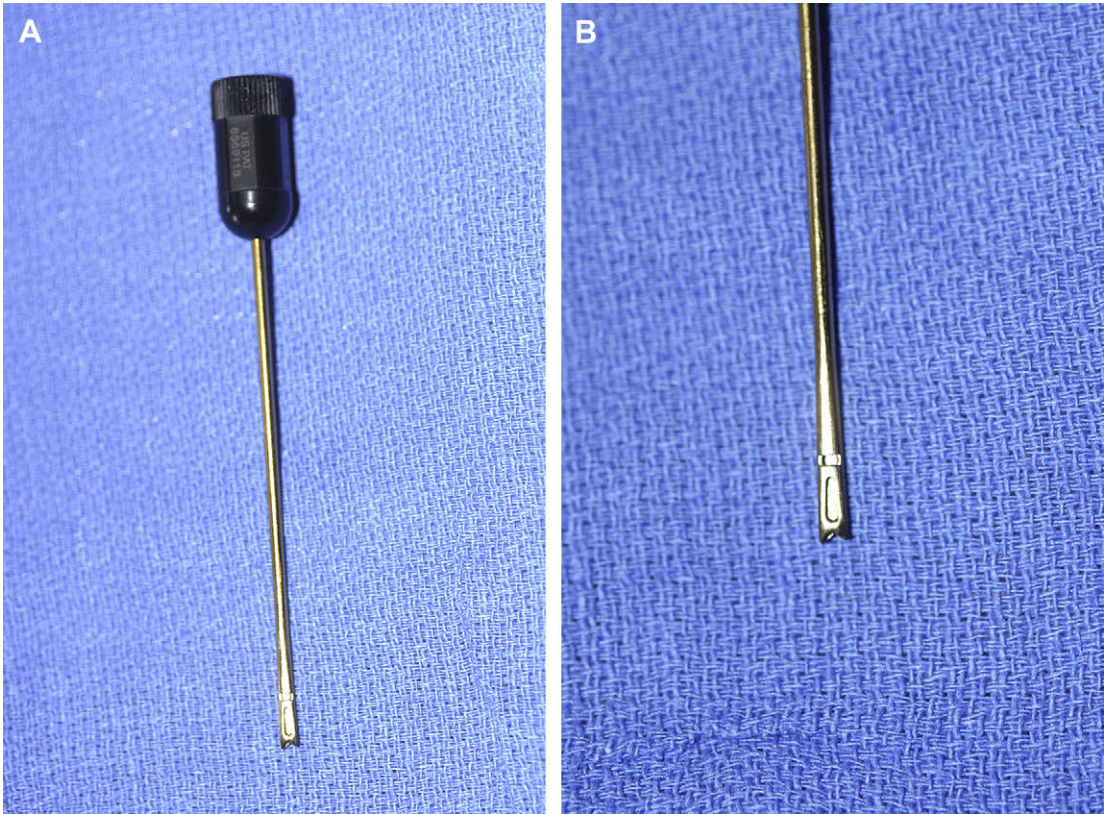


Fig. 7. (A, B) V-dissector allows for controlled release of scar contractures. The dissector should release the contracture as deep as possible. Superficial release with the V-dissector will lead to surface irregularities after fat grafting into the raised areas.

DISCUSSION

As with any surgery, the technique, its execution, and surgeon experience ultimately affect patient outcomes. Fat grafting is not different. The technique should result in maximal survival of

transplanted adipocytes. Attention to minimizing trauma during harvesting of fat, careful preparation during transfer, and, ultimately, the nature of injection are important in determining graft retention.

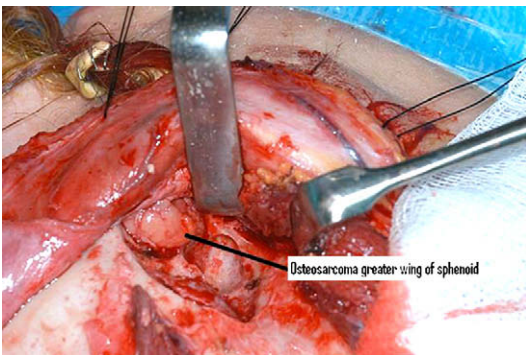


Fig. 8. Intraoperative appearance of an orbitozygomatic approach to resection of an osteosarcoma of the greater wing of the sphenoid.

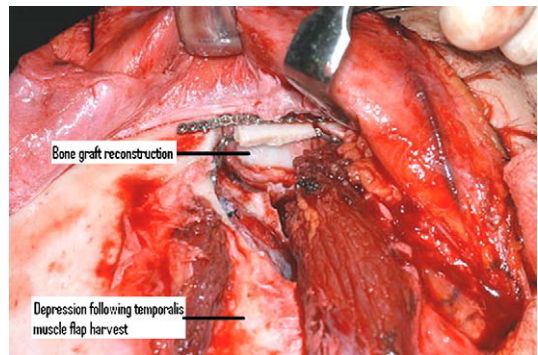


Fig. 9. Intraoperative appearance of patient in Fig. 8 showing calvarial bone graft reconstruction of the orbital rim and walls and temporalis muscle flap reconstruction of the base of the skull. Note the large depression in the temporal fossa after flap harvest.

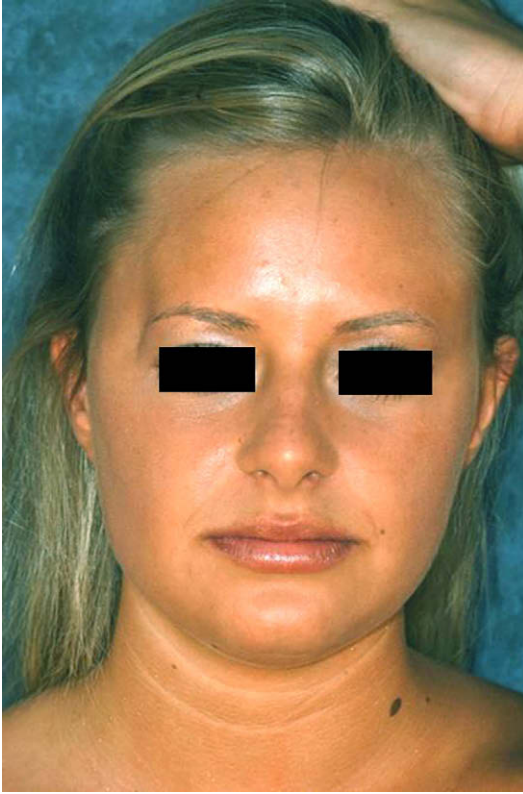

Fig. 10. Three-month postoperative appearance of patient in Fig. 8. Right temporal depression is noted.

Coleman's technique of structural fat grafting results in placement of tiny multiple fat strands with multiple passes.^{13,14} This procedure places the adipocytes close to a recipient blood supply, presumably decreasing risks for resorption. Theoretically, when fat is placed and deposited at the recipient site in large clumps, some adipocytes

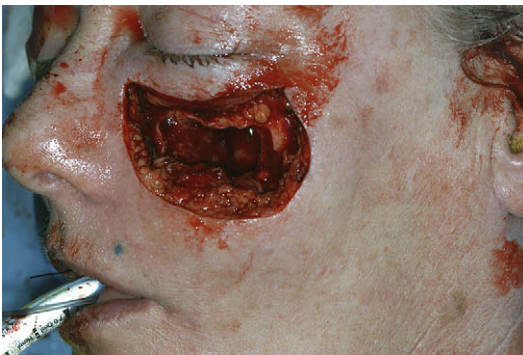

Fig. 12. Intraoperative view of patient status post resection of a recurrent myoepithelioma leaving her with a full thickness defect of the left cheek skin, loss of facial nerve and maxillary bone.

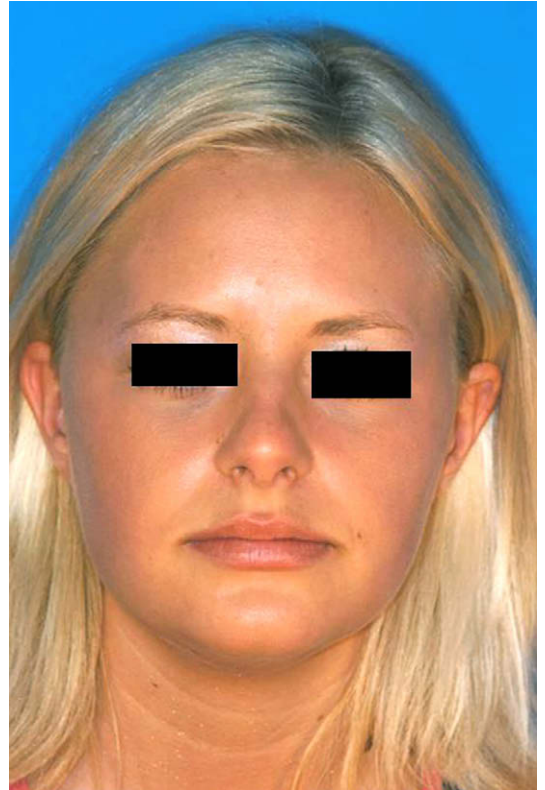


Fig. 11. Eighteen-month postoperative appearance of patient in Fig. 10 after fat grafting to the right temporal fossa. No overcorrection was performed.

will be situated too far from an adequate blood supply, resulting in fat necrosis, which may lead to variable resorption and dreaded surface irregularity.

The problem with this technique is that the multiple passes result in a tremendous increase

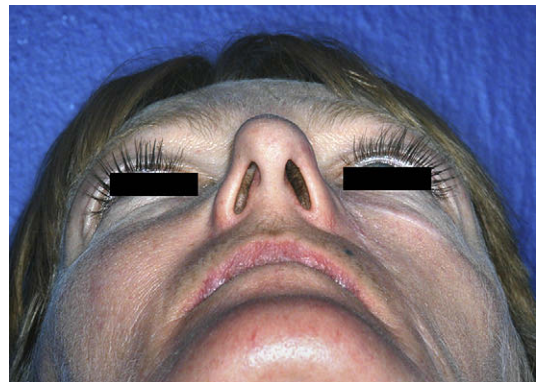


Fig. 13. Following cervicodeltpectoral flap reconstruction of the skin, nerve graft reconstruction of the facial nerve and bone graft reconstruction of the maxilla, this patient, on basal view, is left with volume loss over left cheek.

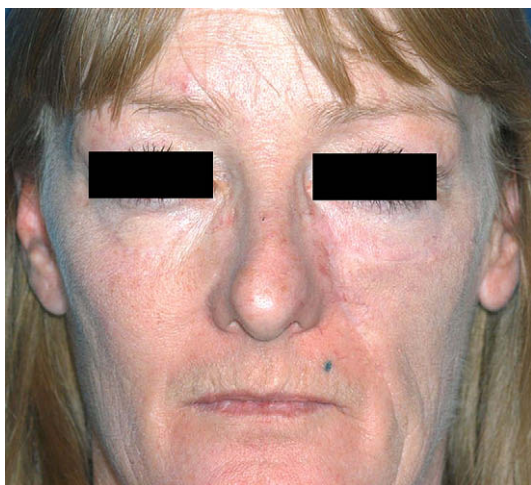

Fig. 14. Frontal view of same patient prior to fat grafting.

in tissue swelling, mobilizing an increased inflammatory response. This effect not only increases the duration of the healing process for the patient but also can result in increased resorption, necessitating overcorrection. In addition, this technique is labor- and time-intensive. The author prefers to inject larger volumes with fewer passes (all fat is injected as the needle is withdrawn from its tunnel) and gently massage the grafts into the recipient site. No overcorrection should be performed with this technique because the author finds that some patients experience no resorption (**Figs. 8–11**). Surface irregularities and healing times have been significantly diminished with this technique.

Although lipotransfer into a radiated recipient bed is associated with an increased risk for resorption, most patients will still experience a favorable improvement.

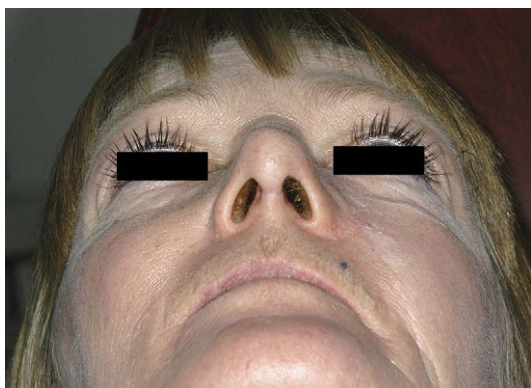

Fig. 15. Following a single lipotransfer to the left face, the patient has improvement in volume on basal view.

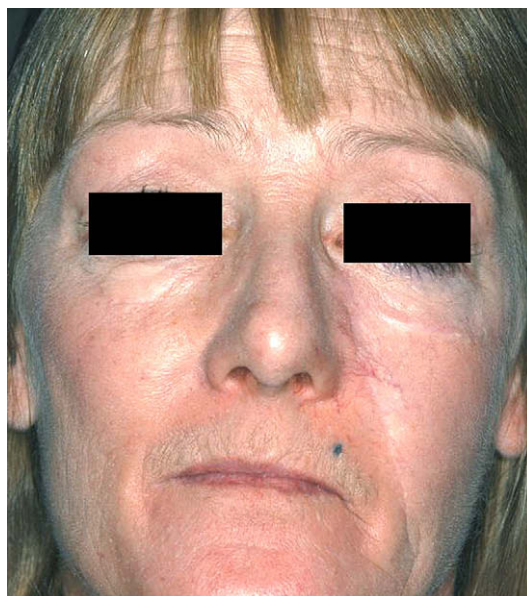

Fig. 16. Frontal view following lipotransfer to left face to complete her reconstruction.

Figures 12 through 16 demonstrate surgical and lipotransfer technique and outcome on a patient with a full thickness skin defect.

SUMMARY

Excellent results may be achieved in most reconstructive and cosmetic surgery cases with well-executed lipotransfer. Attention to detail is important for rewarding results. Graft resorption can occur even in well-executed cases and patients should be appropriately cautioned.

REFERENCES

1. Preston JD. The golden proportion revisited. *J Esthet Dent* 1993;5:247–9.
2. Neuber F. Fet transplantation. *Chir Knogr Verhandl deutsche Gesellsch Chir* 1893;22:66–8.
3. Czerny V. Plastischer ersatz der Brustdruse durch ein Lipom. *Zentralbl Chir* 1895;27:72–5 [German].
4. Pinski KS, Roenigk HH Jr. Autologous fat transplantation: long-term follow-up. *J Dermatol Surg Oncol* 1992;18:179–83.
5. Chajchir A, Benzaquen I. Fat-grafting injection for soft-tissue augmentation. *Plast Reconstr Surg* 1989;84:921–5.
6. Niechajev I, Sevcuk O. Long-term results of fat transplantation: clinical and histologic studies. *Plast Reconstr Surg* 1994;94:496–506.
7. Illouz YG. The fat cell graft: a new technique to fill depressions. *Plast Reconstr Surg* 1986;78:122–6.

8. Smith P, Adams WP Jr, Lipschitz AH, et al. Autologous human fat grafting: effect of harvesting and preparation techniques on adipocyte graft survival. *Plast Reconstr Surg* 2006;117(6):1836–41.
9. Shiffman MA, Mirrafati S. Fat transfer techniques: the effect of harvest and transfer methods on adipocyte viability and review of the literature. *Dermatol Surg* 2001;27:819–23.
10. Ersek RA, Chang P, Salisbury MA. Lipolayering of autologous fat: an improved technique with promising results. *Plast Reconstr Surg* 2002;109:761–6.
11. Ducic Y, Pontius AP, Smith J. Lipotransfer as an adjunct in head and neck reconstruction. *Laryngoscope* 2003;113(9):1600–4.
12. Coleman SR. Fat grafting: more than a permanent filler. *Plast Reconstr Surg* 2006;118(1):108–11.
13. Coleman SR. Techniques of periorbital infiltration. *Oper Tech Plastic Reconstr Surg* 1994;1:120–6.
14. Coleman S. Long term survival of fat transplants: controlled demonstration. *Advances in Plastic Surgery* 1995;19:421–5.