

# Intracranial Free Tissue Transfer for Massive Cerebrospinal Fluid Leaks of the Anterior Cranial Fossa

Jared Inman, MD,\* and Yadranko Ducic, MD†

**Purpose:** The management of large skull base defects with refractory cerebrospinal fluid (CSF) leaks treated with intracranially placed free tissue transfers was examined.

**Materials and Methods:** A retrospective review of all cases of CSF leak presenting to the senior author from 1997 to 2008 in a private tertiary care referral practice was performed. Patients with intracranially placed free flaps were specifically examined for this review.

**Results:** In total 109 patients with skull base defects larger than 4 cm<sup>2</sup> or intractable CSF leaks were identified. Eighty-eight patients underwent reconstruction with local tissue flaps or free tissue grafts. Persistent massive leaks were repaired with 11 intracranial free tissue transfers. CSF fistulas were successfully closed in each instance, with no cases of flap failure or major complications.

**Conclusions:** Intracranial placement of nonskin-bearing free tissue is an excellent treatment alternative for massive CSF leaks and refractory CSF fistulas related to large skull base defects.

© 2012 American Association of Oral and Maxillofacial Surgeons

*J Oral Maxillofac Surg* 70:1114-1118, 2012

Patients with extensive dural injury have an increased risk of meningitis that increases over time (8.6% to 41%) and carries a 10% mortality rate if it develops.<sup>1-4</sup> The cumulative risk of developing meningitis with repaired cerebrospinal fluid (CSF) leaks is only 7%.<sup>5</sup> Dural injuries or skull base defects created during surgery, enlarging pneumocephalus, and persistent CSF leaks

should be addressed immediately. In contrast, spontaneous or post-traumatic CSF leaks with minimal disruption of the skull base and dura usually respond favorably to conservative nonoperative treatment.

Dandy<sup>6</sup> was reported to have closed a cranionasal fistula in 1926 using a frontal craniotomy. In 1966, Ketcham et al<sup>7</sup> reported that their initial attempts at closing CSF leaks resulted in a mortality of 71%. Subsequent large skull base series have shown a morbidity of 25% to 65% and a mortality of 0% to 7.6%.<sup>7-9</sup> High complication rates have led to the increasing use of local and eventually free tissue reconstructions. Moyer et al<sup>10</sup> found that complication rates for local flaps (38.8%) and free flaps (33.5%) were similar and superior to regional flaps (75%). Intracranial repair recently has been associated with 90% initial and 100% secondary attempt closure rates, with a low mortality of 1% to 2%.<sup>1,11</sup>

Occasionally, it may not be possible to treat CSF leaks with conservative treatment or endoscopically. This is particularly evident in patients who have lost a large volume of brain parenchyma, most often because of gunshot wounds to the head requiring surgical debridement of necrotic tissue, and have an associated loss of dural coverage over a broad area of bone loss from the underlying nonsupportive skull base. If the surgeon determines there is adequate tissue to allow for endoscopic closure, this should be attempted first. Normal CSF filling of the potential space left by the loss of brain parenchyma will not occur because of an ongoing loss of fluid through the skull base defect. In addition, "sinking skin-flap syndrome," where differences

---

Received from the Department of Otolaryngology-Head and Neck Surgery at the University of Texas Southwestern Medical Center in Dallas, Texas (Y.D.), From the Baylor Neuroscience Center for Skullbase Surgery Dallas/Fort Worth, Texas (Y.D.), and from Otolaryngology and Facial Plastic Surgery Associates in Fort Worth, Texas (Y.D. and J.I.).

\*Co-director, Baylor Neuroscience Skullbase Program and Clinical Professor, the Department of Otolaryngology-Head and Neck Surgery, the University Southwestern Medical Center.

†The Baylor Neuroscience Center for Skull Base Surgery, Dallas; and Department of Otolaryngology-Head and Neck Surgery, Fort Worth, TX.

Address correspondence and reprint requests to Dr Ducic: John Peter Smith Hospital, Department of Otolaryngology-Head and Neck Surgery, The Baylor Neuroscience Center for Skull Base Surgery, 923 Pennsylvania Avenue, Suite 100, Fort Worth, TX 76104; e-mail: yducic@sbcglobal.net

© 2012 American Association of Oral and Maxillofacial Surgeons

0278-2391/12/7005-0\$36.00/0

doi:10.1016/j.joms.2011.12.025

in intracranial pressure and atmospheric pressure may cause changes in neurologic function, may be improved by vascularized free tissue volumes filling dead spaces and aiding in the vascularity of the wound bed.<sup>12</sup> In such cases, the authors use intracranially inset nonskin-bearing free tissue transfers to seal the skull base defect, provide a platform for brain parenchymal support, and allow for the retention of CSF within the intracranial space. In this article, the authors review their favorable experience with this technique.

## Materials and Methods

A retrospective review of persistent CSF leaks requiring surgical intervention presenting to the senior author (Y.D.) from September 1997 through September 2008 was undertaken. Institutional review board approval was obtained.

### TECHNIQUE

All patients received perioperative antibiotics and steroids. Lumbar drains are not routinely placed. Intracranial placement of the free flap across the skull base is technically simple (Figs 1 to 4). Routinely, tracheotomy is used only for bony defects larger than 4 cm<sup>2</sup>, as previously reported.<sup>13</sup>

If the brain parenchyma volume loss is greater than 30%, a muscle-only free tissue transfer is planned. The rectus flap fat is trimmed as needed to fill the volume deficit during the inset. The muscle portion of the flap should be trimmed only when it has been revascularized. This allows a more accurate assessment of the thickness required to fill the defect. Approximately one half the space between the

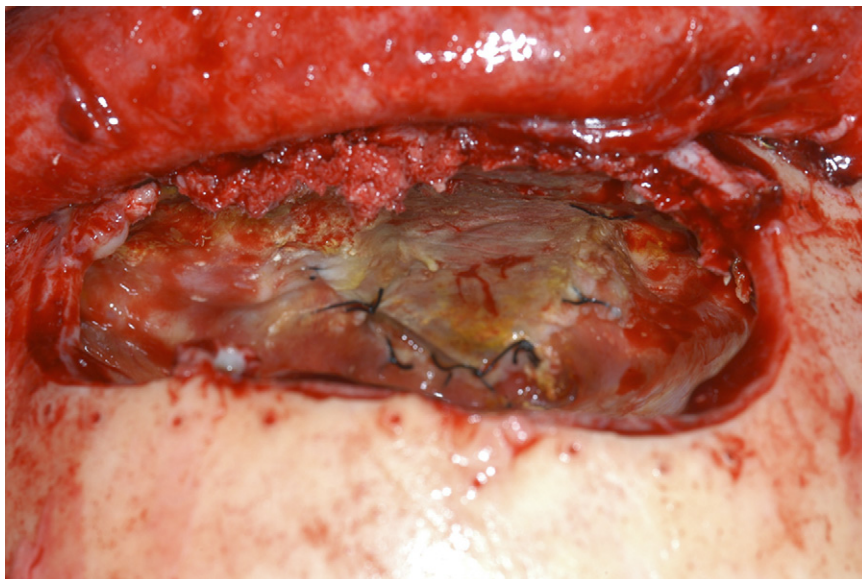retracted remaining brain tissue and the skull base should be filled. One can expect edema in the remaining brain tissue once the leak has been sealed. Edema should be followed by serial computed tomographic scans in the early postoperative period because the neurologic status in this subset of patients is often initially poor (because many were from severe trauma with compromised parenchyma).

If volume replacement is not needed, a radial forearm fascia-only flap appears to be adequate in the authors' experience for reconstructing the defect and providing a watertight separation.

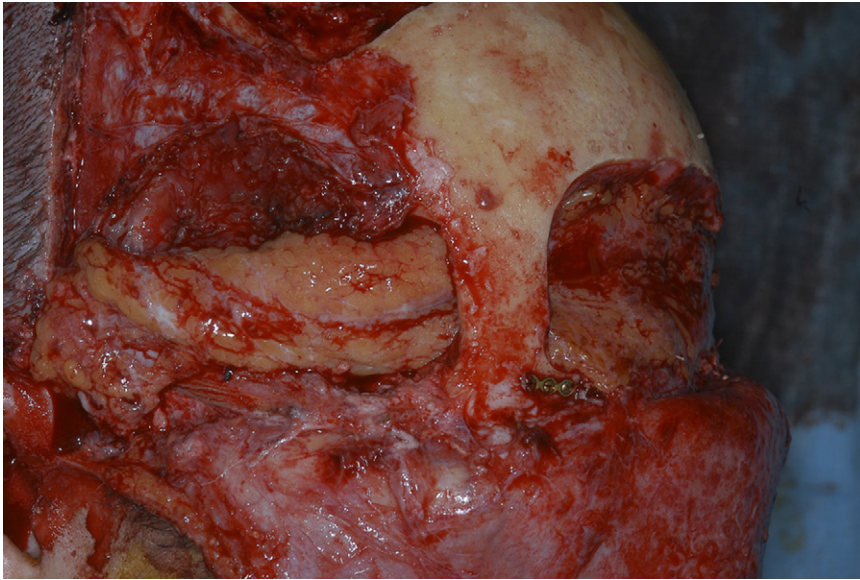
The 2 flaps are inset to overlap the edges of the obvious skull base defects by at least 5 mm. With intracranial exposure, tacking bone tunnel-securing sutures are placed around the flap, if possible. Any dural loss is replaced with grafts. A transcalvarial keyhole is made in the lateral frontotemporal region to the superficial temporal vessels. The artery is always adequate in the authors' experience. If the superficial temporal vein is inadequate, the retromandibular vein usually can be dissected free within the substance of the parotid gland and mobilized for anastomosis. Doppler monitoring is performed. Nasal packing is not routinely needed.

## Results

In total 109 patients with intractable CSF leaks were identified. Eighty-eight patients underwent reconstruction with local flaps (septal, pericranial, temporalis). A subset of 11 patients (8 male, 3 female; average age, 49.5 yrs) underwent 11 intracranially placed free flaps (8 fascia-only radial forearm and 3 muscle-only rectus free

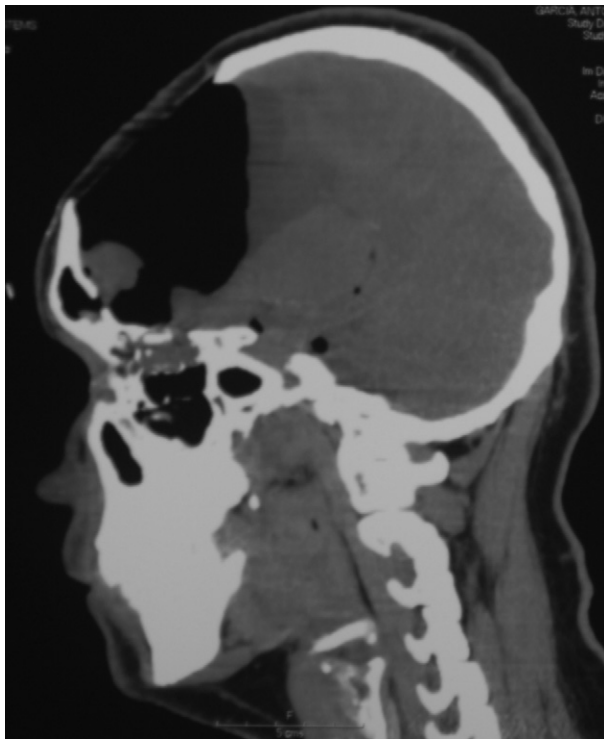


**FIGURE 1.** Intraoperative view of patient after resection of a skull base neoplasm, radiation, and an intractable cerebrospinal fluid leak with a necrotic pericranial flap.



**FIGURE 2.** A radial forearm fascia flap has been applied to the skull base defect and brought out through a keyhole for anastomosis. *Inman and Ducic. Intracranial Tissue Transfer for CSF Leaks. J Oral Maxillofac Surg 2012.*

flaps). All patients had intractable CSF leaks, having failed attempted local flap reconstruction or endoscopic transnasal repair, or a massive volume loss of brain



**FIGURE 3.** Preoperative computed tomogram showing a comminuted skull base and a large defect in the brain with retraction of the remaining brain parenchyma because of an ongoing massive cerebrospinal fluid leak.

*Inman and Ducic. Intracranial Tissue Transfer for CSF Leaks. J Oral Maxillofac Surg 2012.*

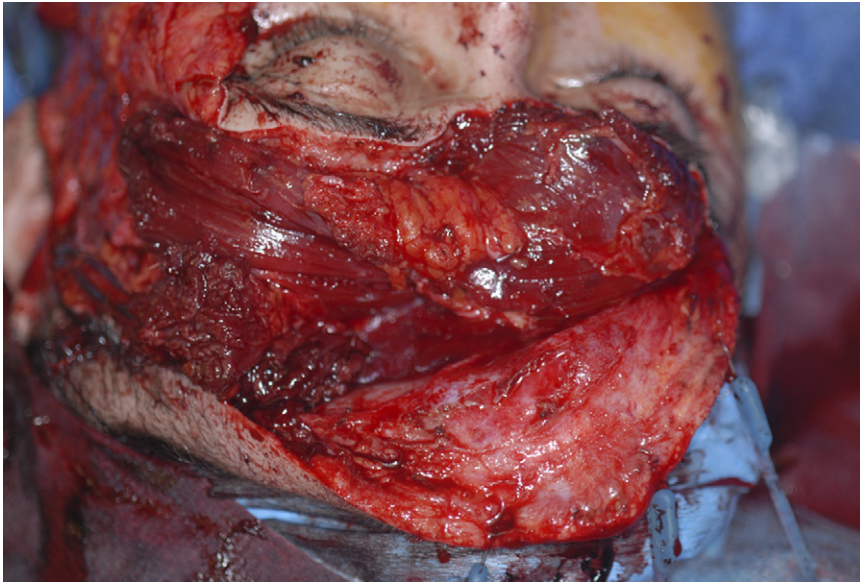parenchyma. Four patients had complex anterior skull base defects (average defect, 15 cm<sup>2</sup>; range, 12 to 21 cm<sup>2</sup>), and 7 patients had massive tissue damage and loss of the supporting local soft tissues, skull base, and brain after gunshot wounds to the head. All flaps were transferred successfully. The superficial temporal vein was inadequate in 6 cases, requiring the use of the retromandibular vein. The vein was mobilized by parotidectomy. All pedicles were passed from the intracranial to the extracranial compartment through a keyhole in the frontotemporal skull. The average operative time was 2 hours 55 minutes. The CSF fistulas were closed successfully in each instance, with no cases of flap failure. No major complications were encountered.

## Discussion

CSF leaks may be addressed by endoscopic, transfacial, and intracranial approaches. In a subset of patients, intracranial vascularized free tissues are preferred. In this series of 109 patients, 88 patients required local tissue flap closures through endoscopic or open approaches. This is preferred when possible.

Closure rates with endoscopic techniques are effective in 86% to 100% of cases.<sup>14</sup> Meta-analyses of 289 endoscopic repairs have shown a 90% primary closure rate with a 95% secondary closure rate.<sup>15,16</sup>

Free tissue transfer to the skull base is especially useful in large defects with extensive or multiple dural injuries. Often local tissue flaps will be damaged beyond salvage by trauma or surgery. Califano et al<sup>17</sup> found a 20% lower complication rate when comparing pedicled with free flaps, but free flaps were per-



**FIGURE 4.** A rectus free flap has been placed intracranially to obliterate the dead space, protect the remaining brain, and close the cerebrospinal fluid leak.

*Inman and Ducic. Intracranial Tissue Transfer for CSF Leaks. J Oral Maxillofac Surg 2012.*

formed for far more extensive defects. Large anterior skull base defects, even in absence of a CSF leak, carry an independent risk for intracranial infection.<sup>1,18</sup> Filling the intracranial dead space with vascularized tissue is also important to support overlying tissues, especially when cranioplasty cannot be performed immediately. It also aides in preventing pneumocephalus and allows for immediate cranioplasty.<sup>12,19,20</sup>

In a review of skull base reconstructions, Neligan et al<sup>21</sup> observed that the distal ends of regional flaps led to breakdown and complications in 75% of patients, whereas the free tissue transfer group had a total complication rate of only 33.5%. Heth et al<sup>22</sup> noted that the local flap group had more late complications compared with the free flap group (23% vs 0%). Free tissue transfer to the skull base offers distinct advantages over local tissue transfer: greater tissue volume availability, improved defect-donor tissue design and esthetic outcomes, decreased complications and recurrent leaks especially in radiated patients, and better success rates in more medial and extensive defects.<sup>10,20,23,24</sup>

A review of 12 patients with prior failed reconstructions and undergoing radial free flaps to the skull base reported that all had resolution of the CSF leak; however, 1 flap-related mortality was reported after an intracranial hemorrhage in the immediate postoperative period.<sup>25</sup> In a review of 35 complex skull base defects (average, 89.3 cm<sup>2</sup>) repaired with free tissue transfer, the mortality rate was 5.7% and the average hospital stay was 13.5 days.<sup>26</sup> The investigators reported 1 flap loss, 3 persistent CSF leaks that resolved with conservative treatment, 1 case each of meningitis, pneumocephalus, and seizure, and 3 strokes.<sup>26</sup>

The intracranial technique described in the present report offers many advantages over other approaches, including the large volume of tissue available, intracranial placement allowing for enhanced visualization and access, and the weight of the remaining brain parenchyma helping with watertight closure. It allows for an improved visualization of the entire extent of the skull base defect and an avoidance of extracranial placement, which has the more inherent risk of flaps pulling away. Moreover, an intracranial approach, with tracheotomy, allows for the avoidance of nasal packing, which is usually necessary to prevent tissues pulling away from the skull base in local or pedicled repairs and to prevent pneumocephalus.

The use of nasal packing historically has been routinely performed to “hold the repair in place” or to decrease risk of pneumocephalus from a Valsalva maneuver. In the 1990s, based on the literature, approximately 60% of investigators were using some form of formal pack or modified packing with Gelfoam, gel film, or fibrin products.<sup>16</sup> Lumbar drains have been proposed to decrease the CSF pressure on grafts, aiding in graft position preservation during adherence; however, only about 50% of studies have reported its routine use and more recent studies rarely have reported using lumbar drains.<sup>16</sup> With an intracranial placement and tracheostomy, it is not the authors’ routine to use any nasal packing or lumbar drain placement.

Timing of repair is difficult to ascertain in acute traumatic injuries. Two meta-analyses of basilar skull fracture have shown that the incidence of meningitis ranges from 9.2% to 17%.<sup>27,28</sup> If a CSF leak is present, it may be as high as 50%, and this risk increases

proportionately over time until 7 to 10 days after a trauma, when the risk is increased 8 to 10 times normal. Despite the risk of meningitis increasing over time, intracranial surgery is not well tolerated in the presence of intracranial edema, with a known mortality rate of up to 25% if performed in the first few days after high-velocity traumas.<sup>27,28</sup> In high-velocity injuries with significant intracranial injury, it is the authors' preference to wait until a patient's neurologic status is stable and then proceed with surgery unless there is significant open trauma with tissue loss, in which case surgery is performed as soon as possible.

Keyhole placement in the frontotemporal region for the vascular pedicle is crucial for inset. It provides direct-line access to the superficial temporal artery and lengthens the pedicle to reach the retromandibular vein, if needed, without a vein graft. The preoperative identification and use of the superficial temporal artery and vein, or the retromandibular vein, if necessary, avoids a vein graft, which lengthens the intraoperative time. Routine use of an implantable or transcutaneous Doppler allows for flap monitoring.

The use of antibiotics in CSF leaks has long been a topic of discussion. Perioperative antibiotics are standard, appearing in more than 94% of cases.<sup>16</sup> A meta-analysis of prophylactic antibiotic use after basilar skull fractures and CSF leaks in 547 patients has shown no significant difference in the development of meningitis between those receiving antibiotics (29/297) and those who did not (34/250).<sup>28</sup> The use of bulky fat fascia flaps is certainly possible, but the authors have not used these in their practice for intracranial placement.

Intracranial free tissue transfer is an effective treatment of large skull base defects after oncologic resection and trauma. Timely vascularized free tissue transfer carries low morbidity and mortality rates. The loss of large amounts of brain tissue in this patient population requires a muscle-bearing flap to fill the dead space adequately. A fascia-only free flap is adequate and recommended in most patients. Historically, intracranial repair has carried a high complication rate. Currently, intracranial placement of vascular free tissue has been used with low rates of morbidity and mortality.

## References

- Scholsem M, Scholtes F, Collignon F, et al: Surgical management of anterior cranial base fractures with cerebrospinal fluid fistulae: A single-institution experience. *Neurosurgery* 62:463, 2008
- Marentette LJ, Valentino J: Traumatic anterior fossa cerebrospinal fluid fistulae and craniofacial considerations. *Otolaryngol Clin North Am* 24:151, 1991
- Villalobos T, Arango C, Kubilis P, et al: Antibiotic prophylaxis after basilar skull fractures: A meta-analysis. *Clin Infect Dis* 27:364, 1998
- Yilmazlar S, Arslan E, Kocaeli H, et al: Cerebrospinal fluid leakage complicating skull base fractures: Analysis of 81 cases. *Neurosurg Rev* 29:64, 2006
- Eljamel M, Foy P: Post-traumatic CSF fistulae, the case for surgical repair. *Br J Neurosurg* 4:479, 1994
- Dandy W: Pneumocephalus (intracranial pneumocele or aereocel). *Arch Surg* 12:949, 1926
- Ketcham AS, Hoye RC, Van Buren JM, et al: Complications of intracranial facial resection for tumors of the paranasal sinuses. *Am J Surg* 112:591, 1966
- Pusic AL, Chen CM, Patel S, et al: Microvascular reconstruction of the skull base: A clinical approach to surgical defect classification and flap selection. *Skull Base* 17:5, 2007
- Ganly I, Patel SG, Singh B, et al: Complications of craniofacial resection for malignant tumors of the skull base: Report of an international collaborative study. *Head Neck* 27:445, 2005
- Moyer JS, Chepeha DB, Teknos TN: Contemporary skull base reconstruction. *Curr Opin Otolaryngol Head Neck Surg* 12:294, 2004
- Calcaterra TC: Diagnosis and management of ethmoid cerebrospinal rhinorrhea. *Otolaryngol Clin North Am* 18:99, 1985
- Schwabegger AH, Rainer C, Laimer I, et al: Hemispheric brain volume replacement with free latissimus dorsi flap as first step in skull reconstruction. *Microsurgery* 25:325, 2005
- Ducic Y, Zuzukin V: A rational approach to the use of tracheotomy in surgery of the anterior skull base. *Laryngoscope* 118:204, 2008
- Zapalac JS, Marple BF, Schwade ND: Skull base cerebrospinal fluid fistulas: A comprehensive diagnostic algorithm. *Otolaryngol Head Neck Surg* 126:669, 2002
- Briggs RJ, Wormald PJ: Endoscopic transnasal intradural repair of anterior skull base cerebrospinal fluid fistulae. *J Clin Neurosci* 11:597, 2004
- Hegazy HM, Carrau RL, Snyderman CH, et al: Transnasal endoscopic repair of cerebrospinal fluid rhinorrhea: A meta-analysis. *Laryngoscope* 110:1166, 2000
- Califano J, Cordeiro PG, Disa JJ, et al: Anterior cranial base reconstruction using free tissue transfer: Changing trends. *Head Neck* 25:89, 2003
- Rocchi G, Caroli E, Belli E, et al: Severe craniofacial fractures with frontobasal involvement and cerebrospinal fluid fistula: Indications for surgical repair. *Surg Neurol* 63:559, 2005
- Levine S, Garfein ES, Weiner H, et al: Intracranial microvascular free flaps. *J Reconstr Microsurg* 25:89, 2009
- Chang DW, Langstein HN, Gupta A, et al: Reconstructive management of cranial base defects after tumor ablation. *Plast Reconstr Surg* 107:1346, 2001
- Neligan P, Mulholland S, Irish J, et al: Flap selection in cranial base reconstruction. *Plast Reconstr Surg* 98:1159, 2001
- Heth JA, Funk GF, Karnell LH, et al: Free tissue transfer and local flap complications in anterior and anterolateral skull base surgery. *Head Neck* 24:901, 2002
- Chepeha DB, Wang SJ, Marentette LJ, et al: Radial forearm free tissue transfer reduces complications in salvage skull base surgery. *Otolaryngol Head Neck Surg* 131:958, 2004
- Donald PJ: Complications in skull base surgery for malignancy. *Laryngoscope* 109:1959, 1999
- Weber SM, Kim J, Delashaw JB, et al: Radial forearm free tissue transfer in the management of persistent cerebrospinal fluid leaks. *Laryngoscope* 115:968, 2005
- Teknos TN, Smith JC, Day TA, et al: Microvascular free tissue transfer in reconstructing skull base defects: Lessons learned. *Laryngoscope* 112:1871, 2002
- Brodie HA, Thompson TC: Management of complications from 820 temporal bone fractures. *Am J Otol* 18:188, 1997
- Villalobos T, Arango C, Kubilis P, et al: Antibiotic prophylaxis after basilar skull fractures: A meta-analysis. *CID* 27:364, 1998