

Metastatic breast cancer of the oral cavity

Robert Todd Adelson, MD^a, Robert J. DeFatta, MD, PhD^a, Brett A. Miles, MD, DDS^b,
Steven L. Hoblitt, MD^c, Yadranko Ducic, MD, FRCS(C), FACS^{a,d,*}

^aDepartment of Otolaryngology-Head and Neck Surgery, University of Texas Southwestern Medical Center, Dallas, TX, USA

^bDepartment of Oral and Maxillofacial Surgery, University of Texas Southwestern Medical Center, Dallas, TX, USA

^cDepartment of Pathology, John Peter Smith Hospital, Fort Worth, TX, USA

^dDivision of Otolaryngology and Facial Plastic Surgery, John Peter Smith Hospital, Fort Worth, TX, USA

Received 16 September 2004

Abstract

Objective: To present a rare case of breast carcinoma initially presenting as an oral cavity mass.

Study design: Case report with review of the literature.

Results: A case is presented of a postmenopausal woman with a remote history of treated breast carcinoma who was declared disease-free 2 years before presentation. She presented with an enlarging vestibule mass consistent with metastatic breast carcinoma. Subsequent investigations revealed widely metastatic disease for which the patient was referred for palliative chemotherapy.

Conclusions: Metastatic disease to the oral cavity represents only 1% of all oral cavity malignancies. A high index of clinical suspicion is necessary when evaluating patients with a history of non-head and neck carcinoma.

© 2005 Elsevier Inc. All rights reserved.

1. Introduction

Metastatic disease represents 1% of all oral cavity malignancies, with 90% of metastases located in either the mandible or the maxilla, and 10% involving the soft tissues of the oral cavity [1–3]. Bony metastases of the oral cavity are 3 times more likely with breast cancer than with any other malignancy; however, breast cancer metastases rarely result in soft tissue oral cavity disease [3,4]. In this report we will describe a case of metastatic breast cancer presenting as a mass involving only the soft tissues of the oral cavity.

2. Case report

A 48-year-old white woman with a 2-month history of a right oral vestibular mass was referred to the Otolaryngology service at our institution for further management. A small incisional biopsy performed on this mass at an outside facility returned a diagnosis of poorly differentiated

adenocarcinoma consistent with metastatic disease. Physical examination of the head and neck revealed a firm 2-cm² submucosal mass located within the right oral vestibule; no other oral cavity lesions were noted. Symptoms attributed to the lesion included simple mass effect, pain, and hypoesthesia of the right mental nerve distribution. The remainder of the patient's complete head and neck examination was within normal limits. The patient's review of systems and complete physical examination was similarly unrevealing without findings of acute changes in health or any evidence of further distant metastatic disease, including other subcutaneous metastases.

Given the concern that this lesion represents metastatic disease, we reviewed the patient's past medical history and discovered she had completed combined modality therapy for breast cancer 2 years before presentation.

The patient was diagnosed in October 1995 with postmenopausal stage III-B invasive adenocarcinoma of the left breast. She underwent cytoreductive systemic neoadjuvant chemotherapy followed by left mastectomy and lymph node sampling. Reconstruction of the left breast with a transverse rectus abdominis muscle flap was performed in early 1996. Metastatic disease was recovered from the axillary lymph nodes, and this was addressed with adjuvant

* Corresponding author. Department of Otolaryngology and Facial Plastic Surgery, John Peter Smith Hospital, Fort Worth, TX 76104, USA. Tel.: +1 817 927 1171; fax: +1 817 927 1605.

E-mail address: yducic@sbcglobal.net (Y. Ducic).

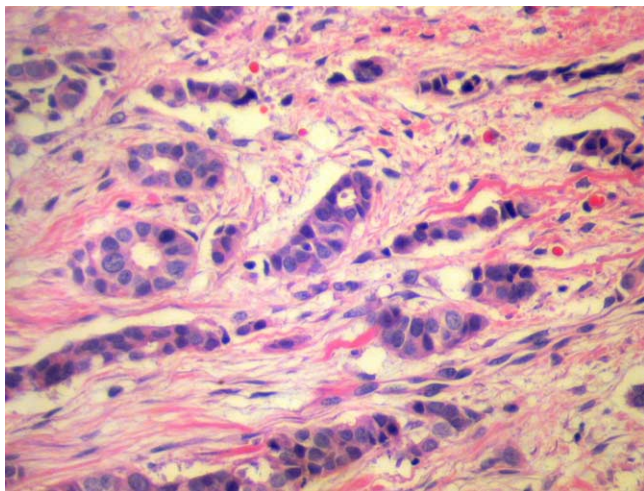


Fig. 1. (High power) Hematoxylin and eosin stain demonstrates malignant glands forming tubules with large pleomorphic nuclei consistent with breast adenocarcinoma.

chemotherapy and nodal external beam radiation therapy. The patient began a planned 5-year course of tamoxifen in November 1996, had close, reliable follow-up exams with the Hematology-Oncology service, and, in November 2001, she was pronounced free of disease and discontinued tamoxifen therapy. Her general medical condition was stable and she reported herself to be at baseline health when she presented to the Otolaryngology service for evaluation of her right vestibular mass in October 2003.

Complete excision of the mass was recommended to the patient both for relief of mass-related symptoms and to provide sufficient tissue for immunohistochemical analysis and definitive diagnosis. An uncomplicated resection of this soft tissue mass under general anesthesia was performed, and the pathology results were consistent with metastatic breast adenocarcinoma. Histopathology demonstrates malignant glands forming tubules with large

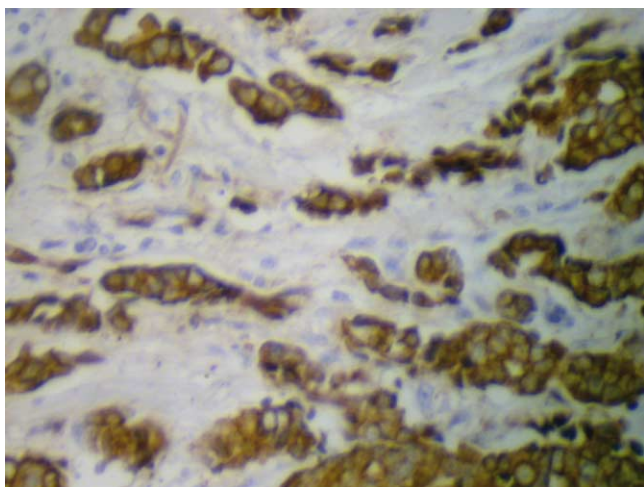


Fig. 2. (High power) CK7 immunostaining demonstrates an epithelial origin of the tumor cells.

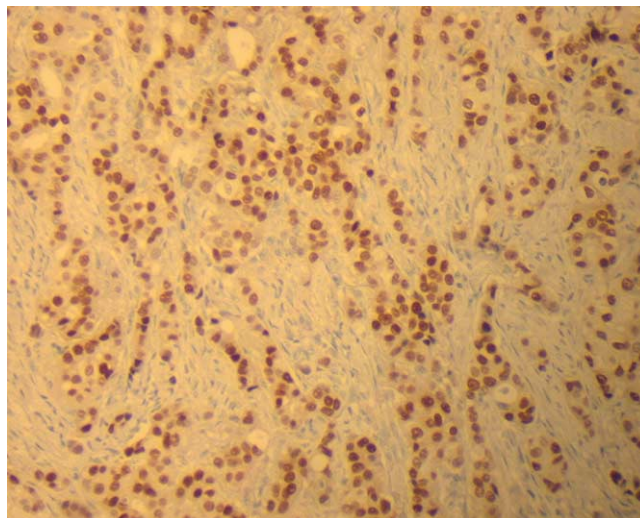


Fig. 3. (Medium power) Estrogen receptor staining confirms a breast cancer origin of the malignant cells streaming in "Indian-file" lines through the specimen.

pleomorphic hyperchromatic nuclei as well as the classic "Indian-file" lines of malignant cells, which is histologically consistent with a primary breast carcinoma (Fig. 1). Cytokeratin-7 immunostaining confirmed an epithelial origin of the tumor cells (Fig. 2), and estrogen receptor immunostaining confirmed the breast origin of the tumor cells as they are seen forming prominent single-file lines coursing through the specimen (Fig. 3).

Based on the final pathology results, a metastatic workup was initiated, including laboratory evaluation and appropriate imaging studies. Magnetic resonance imaging of the brain demonstrated multiple contrast enhancing lesions (≤ 3 mm) consistent with metastatic disease; similarly, computed tomography scan of the chest revealed multiple subcentimeter nodules throughout the lung parenchyma consistent with metastatic disease. The patient's laboratory evaluation, mammography, and computed tomography scans of the abdomen and pelvis were unremarkable. She has been referred for palliative chemotherapy.

3. Discussion

Although unusual, metastatic lesions comprise 1% of all oral cavity malignancies [1-3]. Bony metastases are more common than soft tissue metastases by a ratio of 9:1. Ninety percent of oral cavity metastases involve the mandible or maxilla, and together these locations comprise less than 1% of all lesions metastatic to bone [5]. Metastatic deposits are more common in the mandible when compared with the maxilla, with large case series reporting oral cavity bony metastases to be located in the mandible in 61% to 83% of cases [3,6].

Disease metastatic to the soft tissues of the oral cavity is considered extremely rare, representing less than 0.1% of oral cavity malignancies [4,7]. In Zachariades' [2] review of

422 metastatic oral cavity lesions, only 12 (2.8%) involved soft tissues of the oral cavity. When the soft tissues of the oral cavity are involved with metastatic disease, the attached gingiva is the most common location, followed by the tongue [1].

Primary tumors have various propensities for metastasizing to the oral cavity. Several authors report that adenocarcinoma is the most common histologic type, and that breast adenocarcinoma is the most common malignancy that metastasizes to the mandible or maxilla [3,5,7]. In fact, breast cancer seems to have a particular proclivity for metastasizing to the mandible, as it does so 3 times as frequently as do other malignant tumors [4,5]. Conversely, Eckardt and Nommels [4] consider breast cancer metastatic to the soft tissues of the oral cavity “extremely rare.” In some series these comprise less than one third of the cases of oral cavity breast metastases [3,4].

Regardless of the tumor of origin, oral cavity metastases are reported as the first clinical indication of a primary malignancy in 22% to 33% of patients [1,2,5]. Although our patient had a history of breast adenocarcinoma, she was believed to have been cured at the time of presentation to our service, nearly 8 years after her initial diagnosis. Subsequent complete workup revealed widely metastatic disease. Four-year survival for this patient population has been estimated by Rocha et al [6] to be 10%. Given the extent of our patient’s metastatic burden and the low probability of achieving a cure, she has been referred for palliative chemotherapy.

4. Conclusion

We present a rare case of metastatic breast adenocarcinoma presenting with findings limited to the oral cavity. Otolaryngologists should be reminded that 1% of oral cavity malignancies represent metastatic disease, and on such occasions our specialty will have the opportunity to diagnose an unsuspected malignancy arising from a distant site. This reinforces the necessity of maintaining a high index of suspicion for metastatic lesions, even in the most unlikely locations, when examining patients with a personal history of malignancy.

References

- [1] Hirshberg A, Buchner A. Metastatic tumours to the oral region. An overview. *Oral Oncol* 1995;31:355-60.
- [2] Zachariades N. Neoplasms metastatic to the mouth, jaws and surrounding tissues. *J Craniomaxillofac Surg* 1989;17:283-90.
- [3] van der Waal RIF, Buter J, van der Waal I. Oral metastases: report of 24 cases. *Br J Oral Maxillofac Surg* 2003;41:3-6.
- [4] Eckardt A, Nommels R. Breast carcinoma metastatic to the gingiva. *J Oral Maxillofac Surg* 1986;44:902-5.
- [5] Stavropoulos MF, Ord RA. Lobular adenocarcinoma of breast metastatic to the mandibular condyle. *Oral Surg Oral Med Oral Pathol* 1993;75:575-8.
- [6] Rocha WC, Curado MP, Vencio EF, et al. Endometrial carcinoma metastatic to the mandible: a case report. *J Oral Maxillofac Surg* 2000;58:914-6.
- [7] Epstein JB, Knowling MA, Le Riche JC. Multiple gingival metastases from angiosarcoma of the breast. *Oral Surg Oral Med Oral Pathol* 1987;64:554-7.