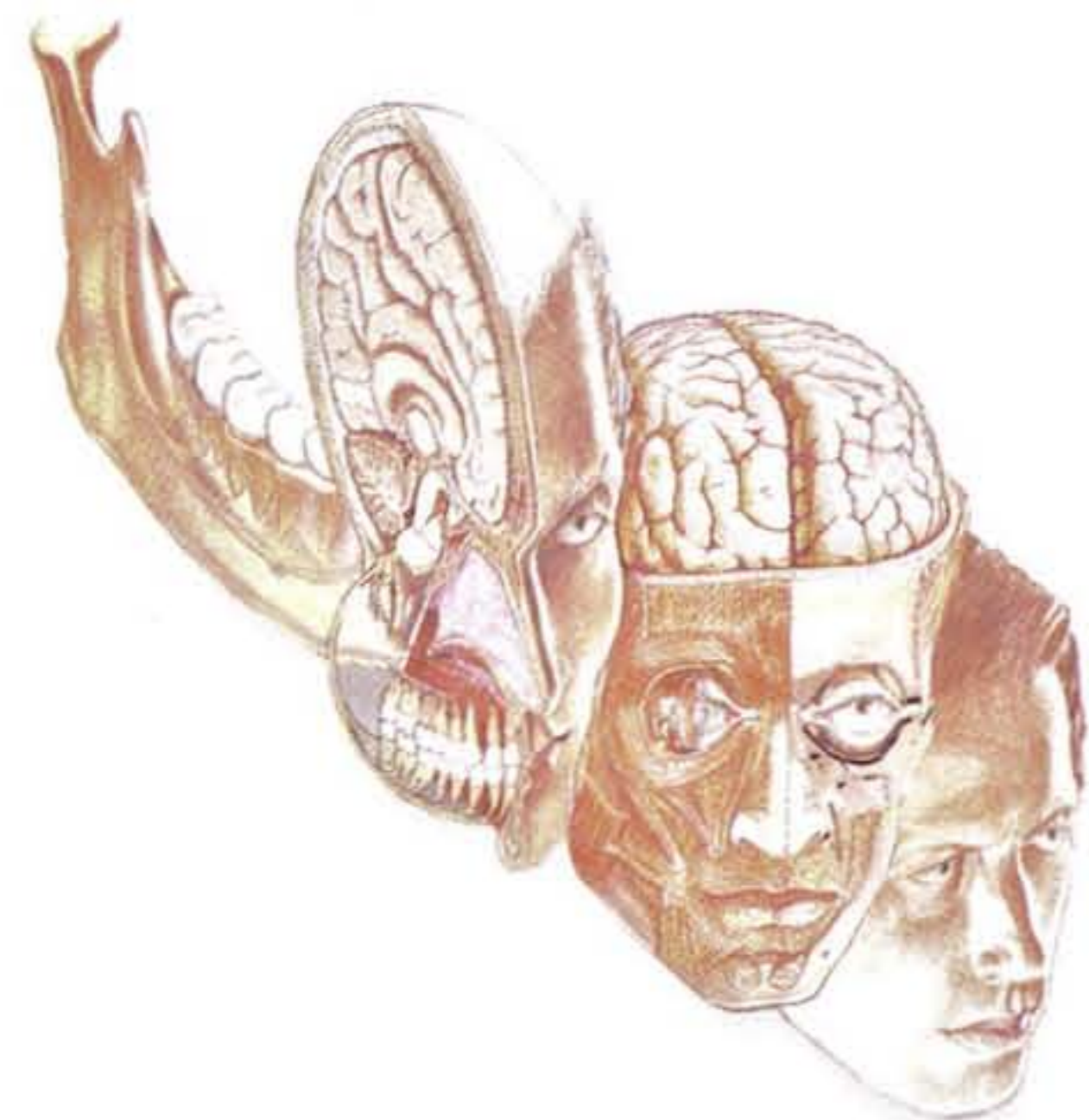



Midface Reconstruction With Titanium Mesh and Hydroxyapatite Cement: A Case Report

Yadranko Ducic, MD*

ABSTRACT

Reconstruction of the midface following trauma generally involves the simple assemblage of the existing bony fragments with the usage of miniplate osteosynthesis. Fractures of the maxilla are of significant functional as well as aesthetic importance. Occasionally, reestablishment of the bony structure is not possible without the concomitant use of bone grafts to replace areas where bone loss is present due to extensive comminution. Calvarial bone grafts are often used; however, they are not ideal, due to donor site morbidity, resorption, and difficulty in contouring the grafts to the curves of the face. This article will review a case of severe midfacial trauma in which a significant portion of the comminuted midface was successfully reconstructed with titanium mesh and hydroxyapatite cement.

Fractures of the maxilla comprise approximately 15% to 20% of all fractures of the maxillofacial skeleton.^{1,2} Most afflict the young adult male population as a consequence of motor vehicle accidents and assaults.³ These fractures are of significant functional as well as aesthetic importance. In health, the midfacial system of buttresses functionally serves to bridge the upper (fronto-ethmoid and skull base) and lower (occlusal plane) segments of the maxillofacial skeleton. Similarly, the malar eminence represents one of the major aesthetic highlights of the face, making contributions to perceived facial width and projection. Nonrigid fixation techniques, commonly utilized in the past, often allowed for postoperative migration and malrotation of the fractured segments. Presently, wide exposure and the application of rigid internal fixation devices predictably effect favorable outcomes in most patients.

Traditionally, in the repair of midface fractures, large areas of bone "loss" arising as a result of severe comminution have

been bridged with bone grafts rigidly fixated in situ. Resorption is less commonly a difficulty with calvarial bone grafts as compared to bone grafts obtained from other donor sites (e.g., iliac crest, rib). However, calvarial bone grafts are not necessarily ideal. In addition to the donor site morbidity (which is usually not a significant difficulty) and the potential for resorption, calvarial bone grafts are difficult to contour into the delicate, three-dimensional curves that exist in the normal upper midface. An ideal graft would:

- **Have enough stability to withstand the forces of mastication.**
- **Have the potential for graft integration by new bone ingrowth.**
- **Be biocompatible.**
- **Be available in large quantities.**
- **Have no associated donor site morbidity.**
- **Be readily moldable to enable the formation of delicate three-dimensional shapes.**

No such ideal graft has been found to date.

This article will discuss a case of severe midfacial disruption arising from trauma, with subsequent reconstruction using titanium mesh and hydroxyapatite cement.

*Department of Otolaryngology at the University of Texas South Western Medical Center in Dallas, Texas, and the Division of Otolaryngology and Facial Plastic and Reconstructive Surgery at John Peter Smith Hospital, Fort Worth, Texas.

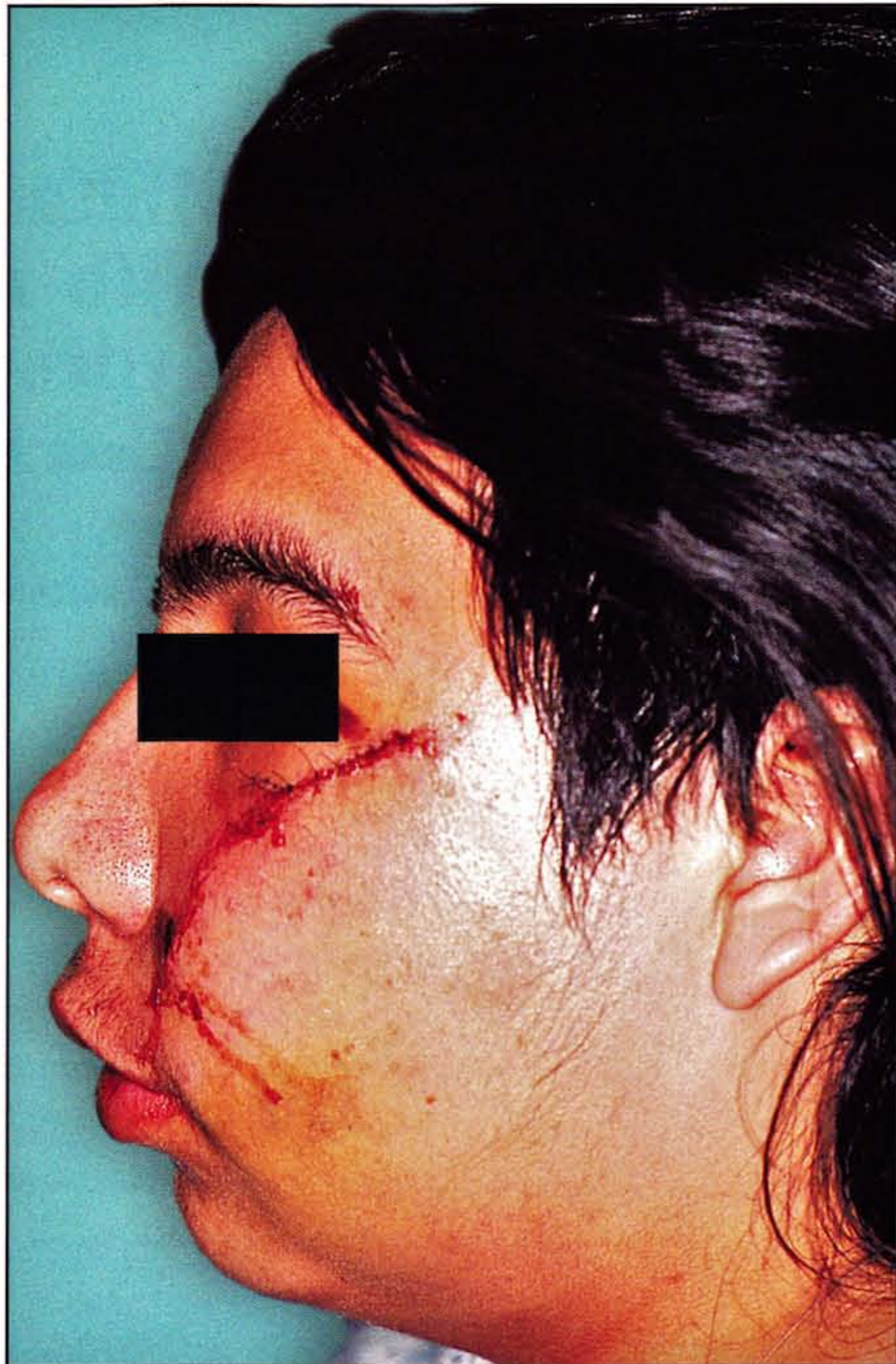
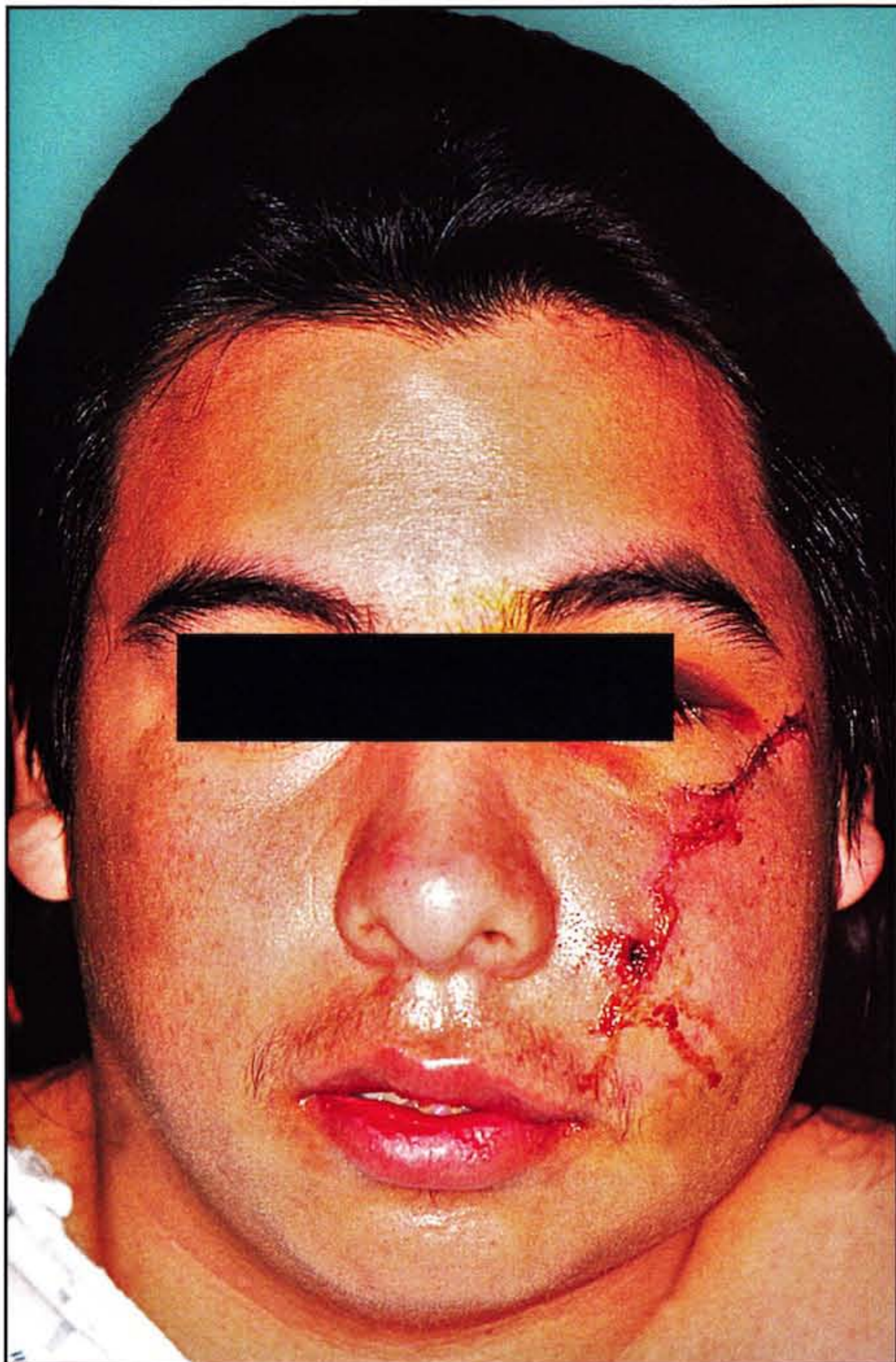
Figure 1. Preoperative frontal view of left midface of patient presented in case report.

Figure 2. Preoperative lateral view exhibiting the large laceration across his left cheek.

CASE REPORT

An 18-year-old Hispanic male pedestrian was struck by a motor vehicle and absorbed a large amount of impact force at the level of his left midface. Clinically, in addition to his maxillofacial skeletal disruption, he had a large laceration overlying his left cheek, and an incomplete palsy of the buccal and zygomatic branches of cranial nerve seven (Figures 1 and 2). Computed tomography (CT) scanning in the axial and coronal planes confirmed the presence of midfacial comminution consistent with the physical examination findings of lack of midfacial support and malocclusion (Figure 3).

Consent for open reduction and internal fixation of his midface fractures was obtained, but the patient did not consent to the use of bone grafts. The patient was brought to the operating room and maxillomandibular fixation was achieved with the use of arch bars in the usual manner. Subsequently, wide exposure was achieved with upper gingivobuccal and upper blepharoplasty incisions, in addition to utilizing the upper part of the patient's existing cheek laceration (it had been a full thickness laceration in this segment). There was severe comminution evident at the level of the malar eminence, and moderate disruption was noted to be present at the anterior wall of the maxilla and lateral

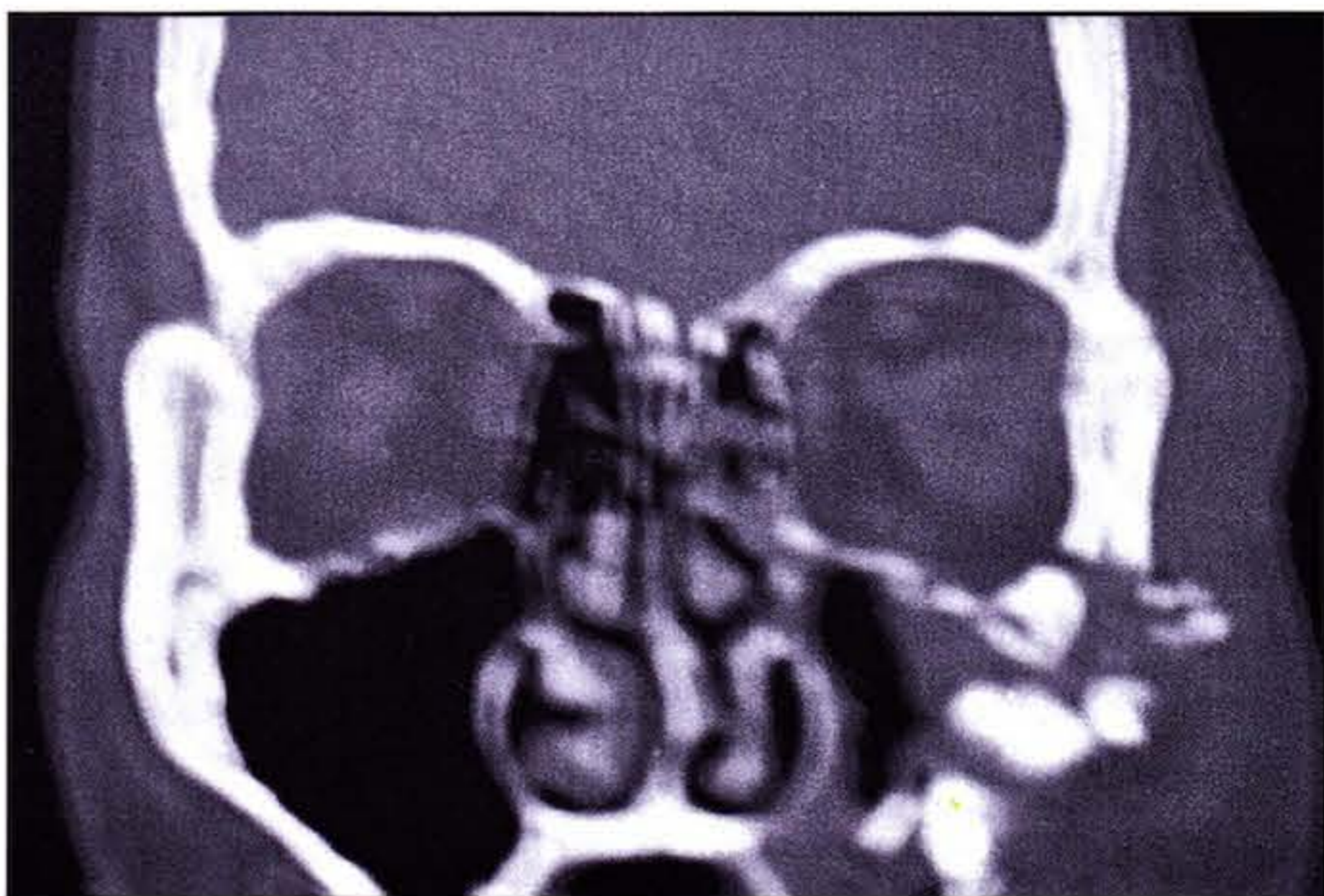


Figure 3. Reconstructed coronal view demonstrating significant comminution of the lateral buttress and body of zygoma.

buttress. The major remaining loose fragments of bone were utilized to reconstruct the inferior half of the lateral buttress, and were fixated in situ with titanium miniplate osteosynthesis (Figure 4). Orbital floor disruption was repaired utilizing titanium mesh fashioned upon a human skull encased in sterile plastic (Figure 5). Wrapping the edges of the titanium mesh with gelfilm permitted easier insertion into the orbit (Figure 6).

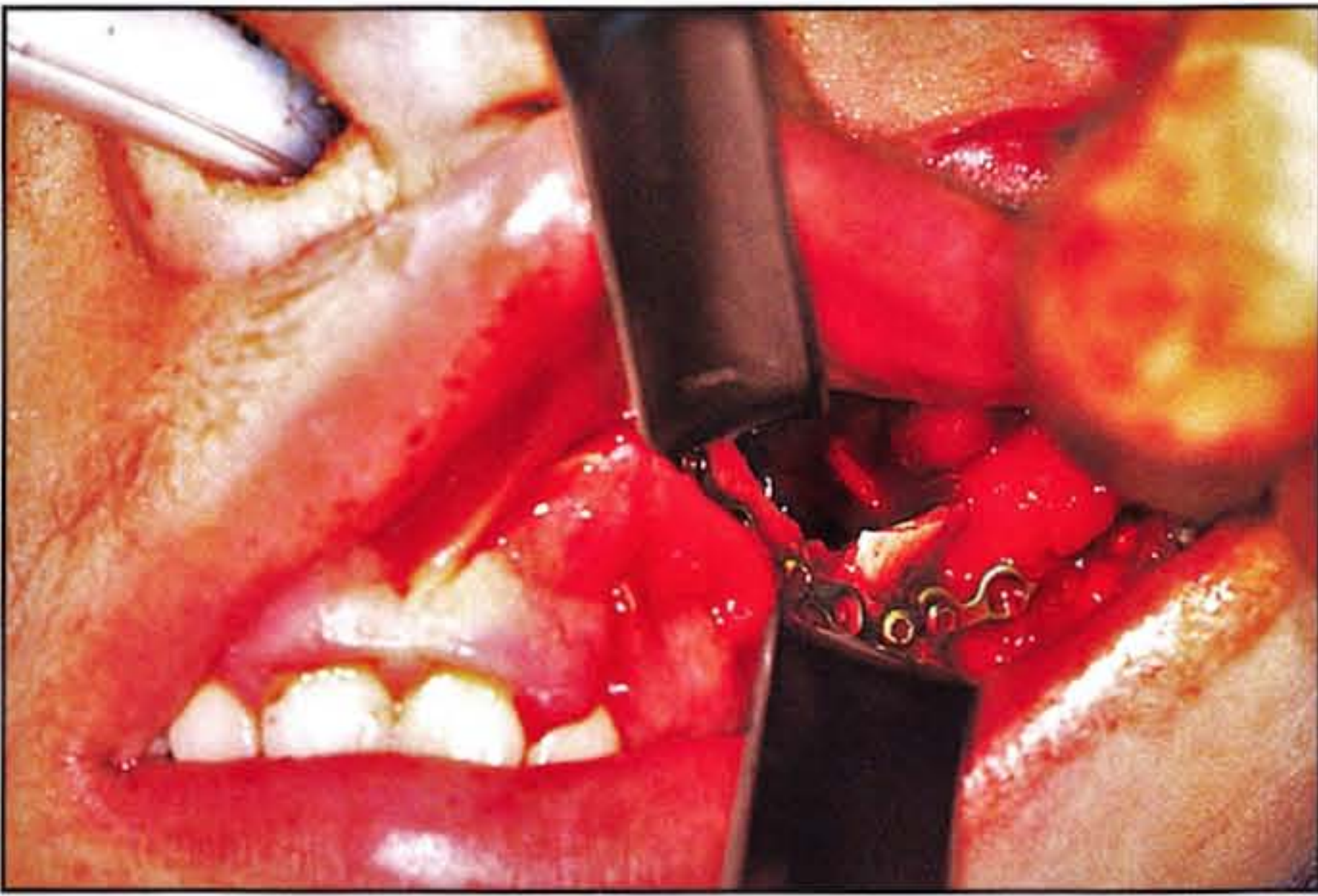

Figure 4. Intraoperative view revealing reconstruction of the inferior half of the lateral buttress with available bone remnants and titanium plate osteosynthesis.

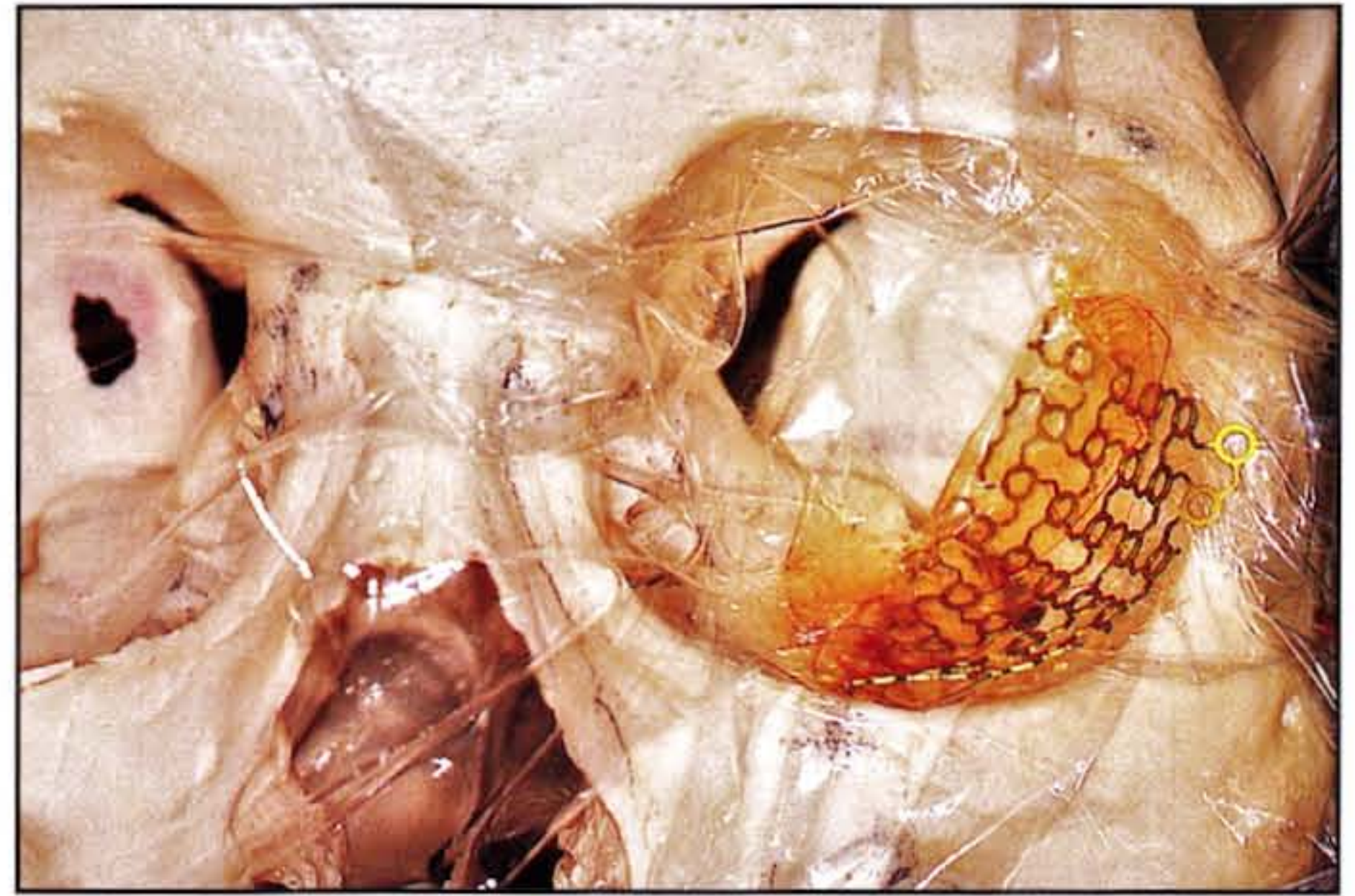

Figure 5. Intraoperative use of a human skull wrapped in a sterile bag demonstrating its utility in initially fashioning titanium mesh for use on various contoured parts of the maxillofacial skeleton.




Figure 6. Titanium mold with edges wrapped in gelfilm to allow for easier insertion into areas of soft tissue.

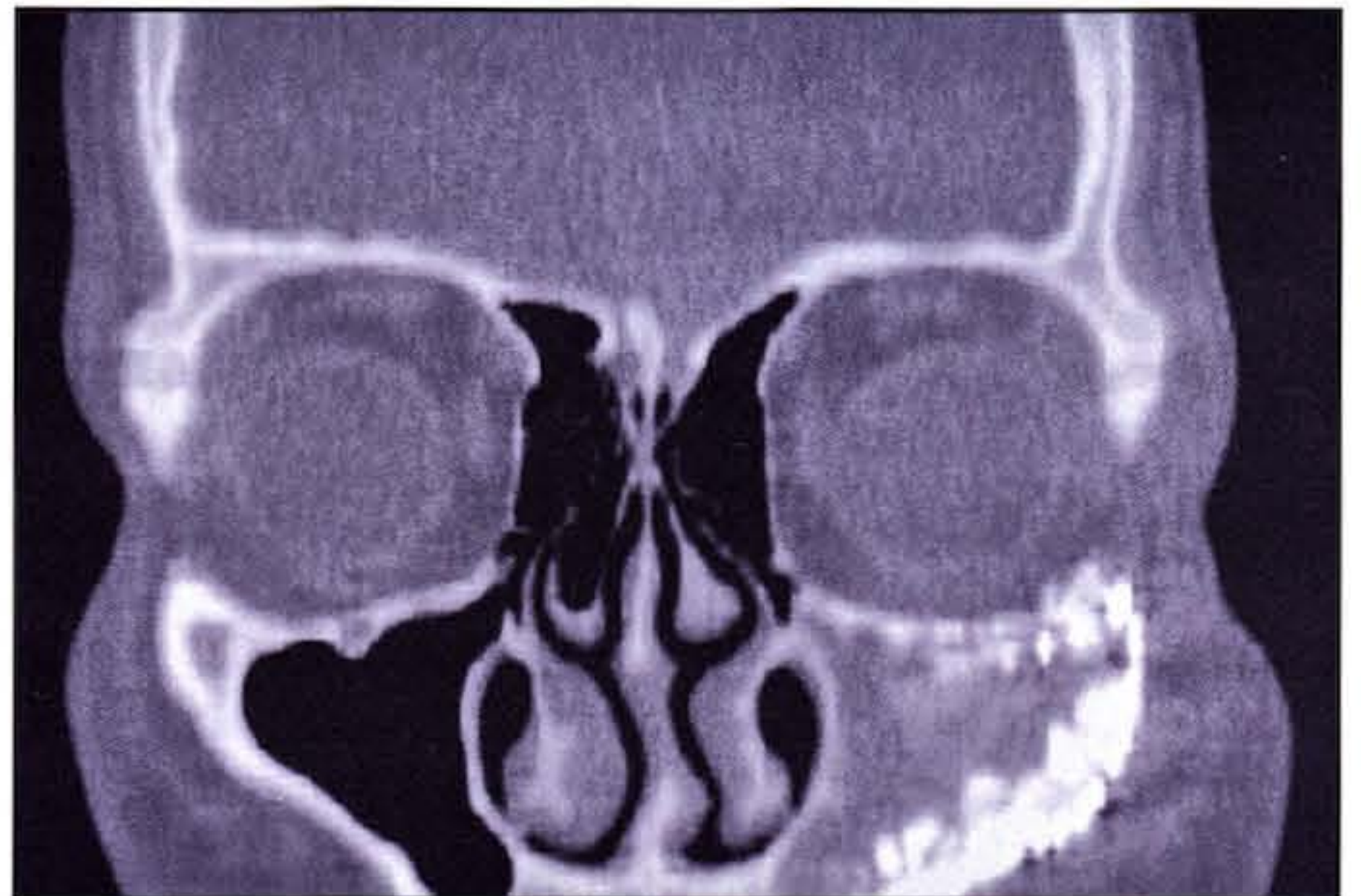


Figure 7. Postoperative true coronal CT scan demonstrating good reestablishment of the bony contours of the midface.

At this point, there was significant persistent midface retrusion due to bone loss. As bone grafts could not be utilized due to lack of consent, in order to maintain underlying support for the overlying soft tissues, a framework reconstruction of the aesthetically and functionally important areas of the midface was required. Thus, 2.0-mm titanium mesh was conformed on the encased human skull to form a model. Mild overcorrection was performed, as it was assumed that some settling of the structure would occur in the immediate postoperative period. At this point, hydroxyapatite cement (BoneSource-Leibinger, Dallas, Texas) was placed onto the titanium mesh that was rigidly fixated in situ. The cement was allowed to set for 30 minutes. The area was copiously irrigated with Betadine Solution (Purdue Frederick Company, Norwalk, CT) at the completion of the procedure, as is the standard practice performed by the author. All access incisions were closed in the usual manner.

The patient was kept in maxillomandibular fixation postoperatively for a period of 4 weeks, after which normal mastication was present. Coronal CT scanning revealed an adequate restoration of the skeletal structure of the midface (Figure 7). However, at this point, the patient's postoperative appearance revealed that the original deliberate overcorrection had not

changed appreciably. Thus, the patient was returned to the operating room 5 weeks after the initial procedure in an attempt to mold the titanium mesh-hydroxyapatite complex (referred to hereafter as the "complex") and ameliorate the patient's aesthetic overcorrection. It was noted that the complex remained with a surrounding mild fibrous reaction (Figure 8). The complex was so rigid that little could be done to mold it. Thus, the upper gingivobuccal access incision was closed and the site left essentially undisturbed. The patient had been unwilling to undergo more than minor revision surgery at that time. Biopsies were taken from the margins and center of the complex at the time of the revision surgery. All sites that were biopsied revealed that initiation of bony integration of the complex had begun (Figures 9 and 10). The patient's postoperative function is excellent. His appearance is acceptable, but initial overcorrection appears not to be required if this method of reconstruction is utilized (Figures 11 and 12).

DISCUSSION

Titanium has been the standard material utilized in the majority of maxillofacial plating systems over the past decade. It is more biocompatible and more resistant to corrosion than either

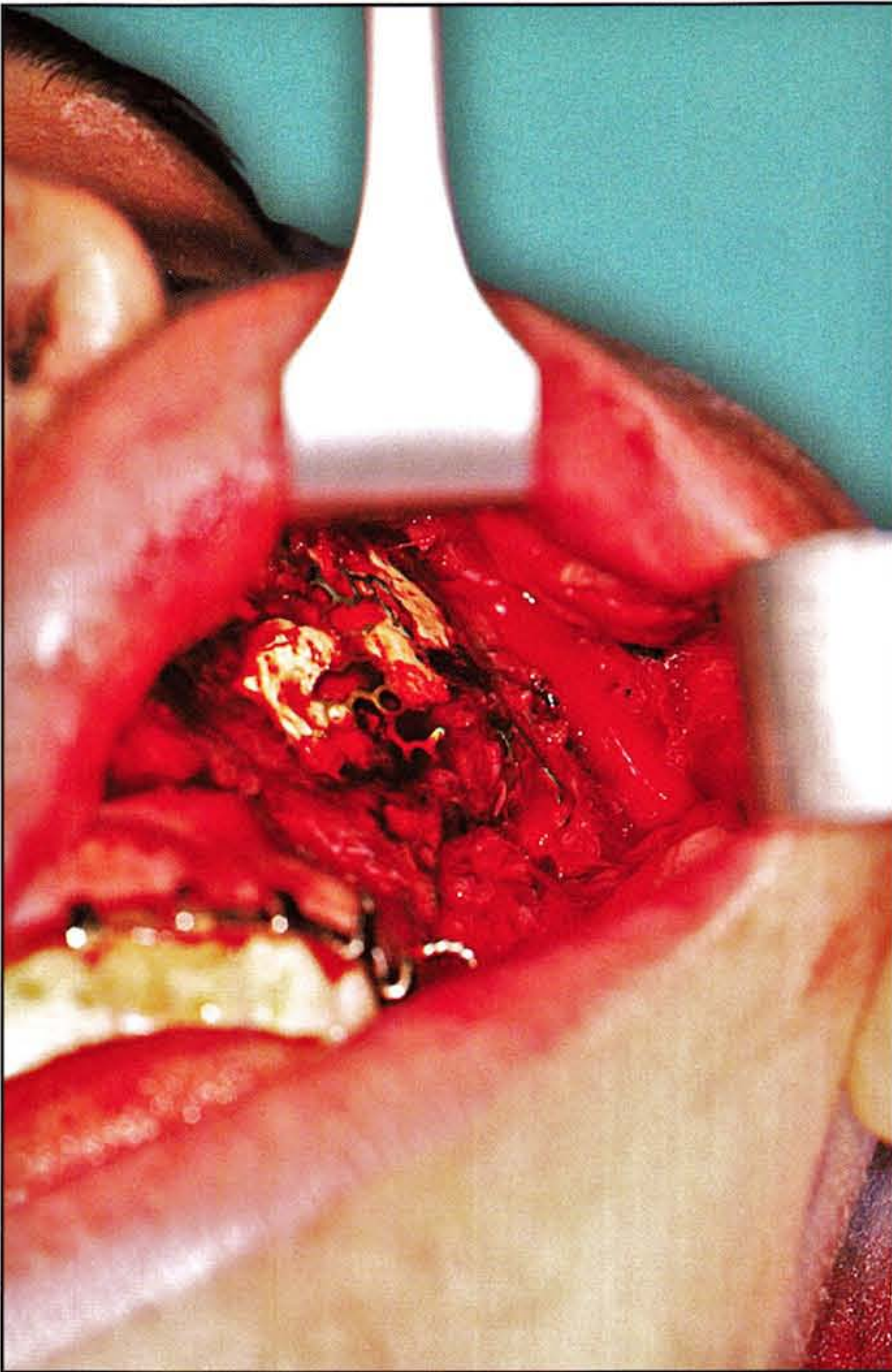

Figure 8. Findings at secondary operation demonstrating persistence of titanium mesh-hydroxyapatite complex.

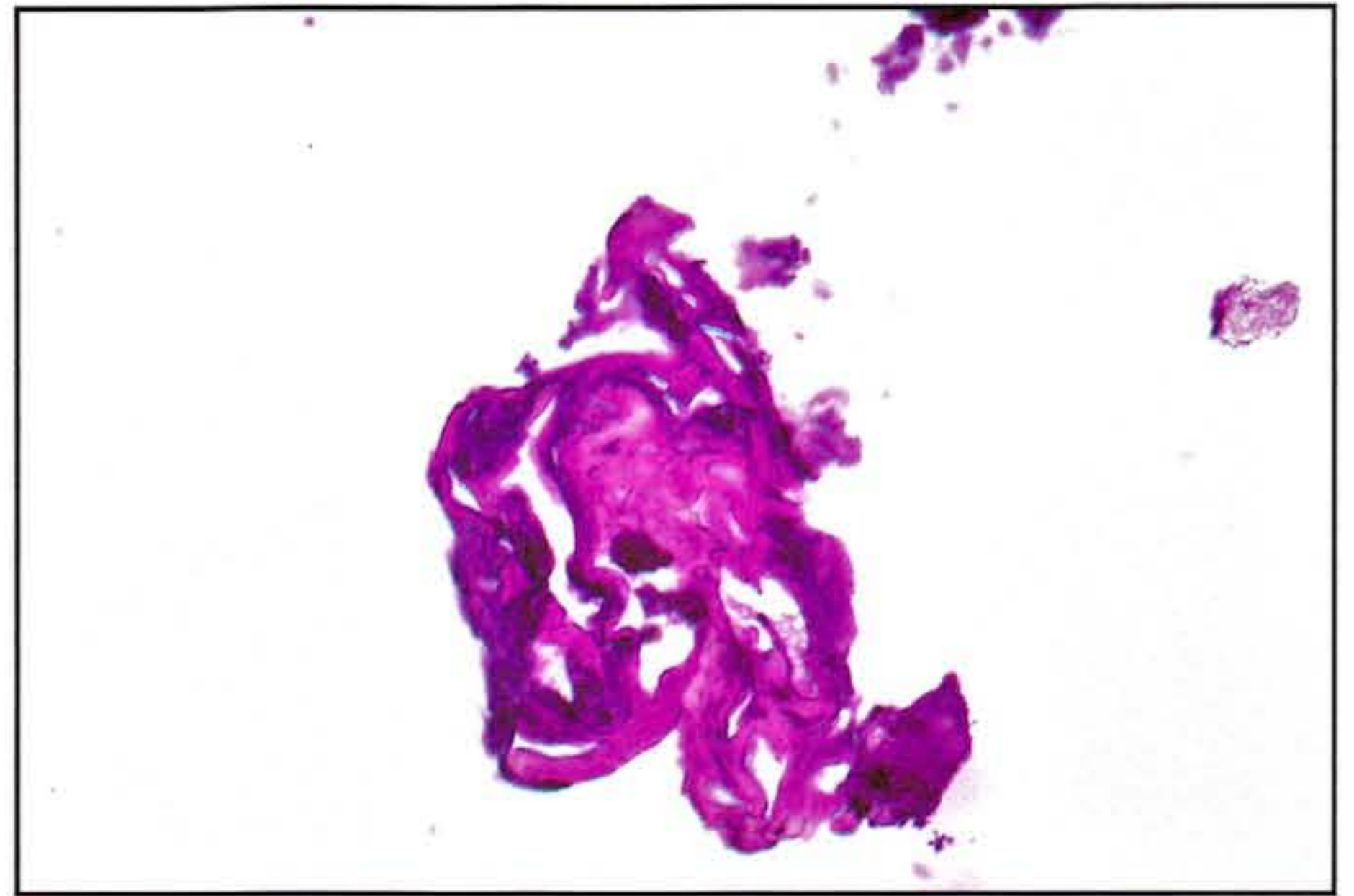


Figure 9. Specimen taken from periphery of complex. Note early bony trabecular ingrowth into hydroxyapatite.

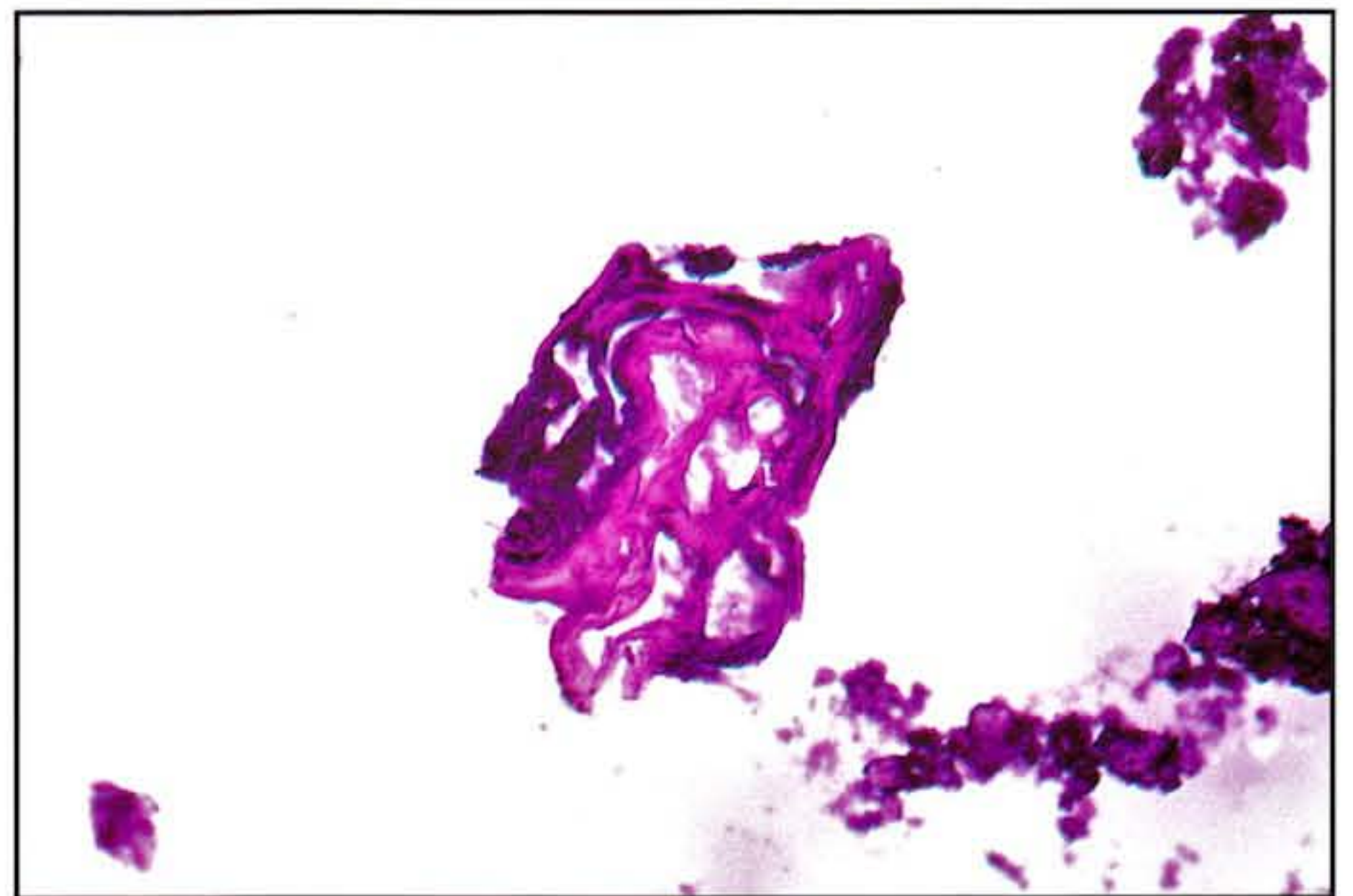


Figure 10. Specimen taken from center of complex. Note findings similar to those in Figure 9.

stainless steel or Vitallium (Howmedica Inc., Rutherford, NJ), the other common components of many plating systems. It also has a favorable modulus of elasticity, approximating that of bone more closely than other components. Generally, titanium plating systems do not require removal, making the possibility of permanent *in vivo* usage feasible.

Hydroxyapatite cement basically consists of interlinked chains of calcium phosphate. Although hydroxyapatite does not appear to be osteogenic (i.e., inducing *de novo* bone formation), it certainly has proven to be osteoconductive, serving as a convenient scaffold for bony ingrowth.^{4,5} The cement form of hydroxyapatite is nonceramic and is set *in vivo* by the addition of water to make it into a paste. This paste form may be contoured into any dry defect, making it ideal for use in cranioplasty.⁶ It has also proven useful in the obliteration of bone cavities created by surgical resection.^{7,8} Once hydroxyapatite cement has been contoured into the desired defect, it should be allowed approximately 30 minutes to set in a relatively dry environment. After the material is fully cured (which takes approximately 4 hours), it acquires a tensile strength that appears to be sufficient for the reconstruction of non-stress-bearing bone.⁹ The addition of titanium mesh would be expected to significantly increase the tensile

strength of hydroxyapatite. This increased strength enabled the complex to withstand significant masticatory forces in the case presented. The exposure of the complex to maxillary sinus mucosa should not pose a significant difficulty, so long as the mucosa is not trapped within the reconstructed frame. A long-term prospective study of this particular point is required.

The combined usage of hydroxyapatite cement on a molded scaffold of titanium mesh has not previously been reported as a reconstructive option in midfacial fracture treatment. The procedure, as outlined, was simple to perform and provided excellent stability as well as maintenance of the three-dimensional structure that had been set at the original surgery. Overcorrection does not appear to be necessary, as was demonstrated. This may be a reasonable alternative in patients for whom bone grafts are either unavailable or disallowed. It is also a reasonable modality to consider using in the reconstruction of parts of the maxillofacial skeleton whose structure is difficult to fully correct with the use of bone grafts. The author has also used the outlined method to reconstruct the inferior orbital rim with success. Although no infections have been noted as yet, the possibility is present with the implantation of any autograft or alloplastic material. However, studies have found a relative paucity of infections noted in association with

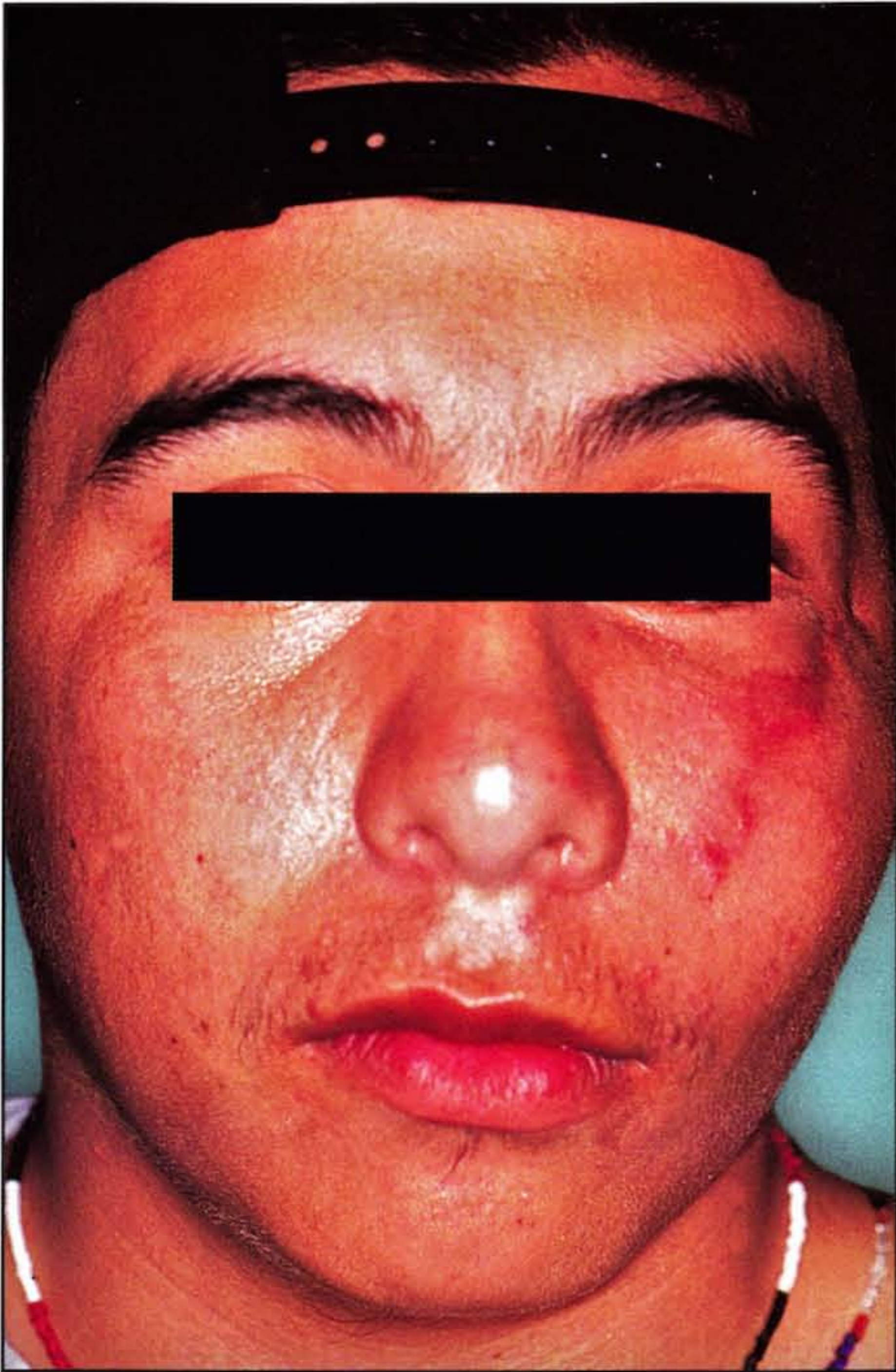

Figure 11. Postoperative frontal view of patient. Note persistence of overcorrection that had been established at the primary operation.

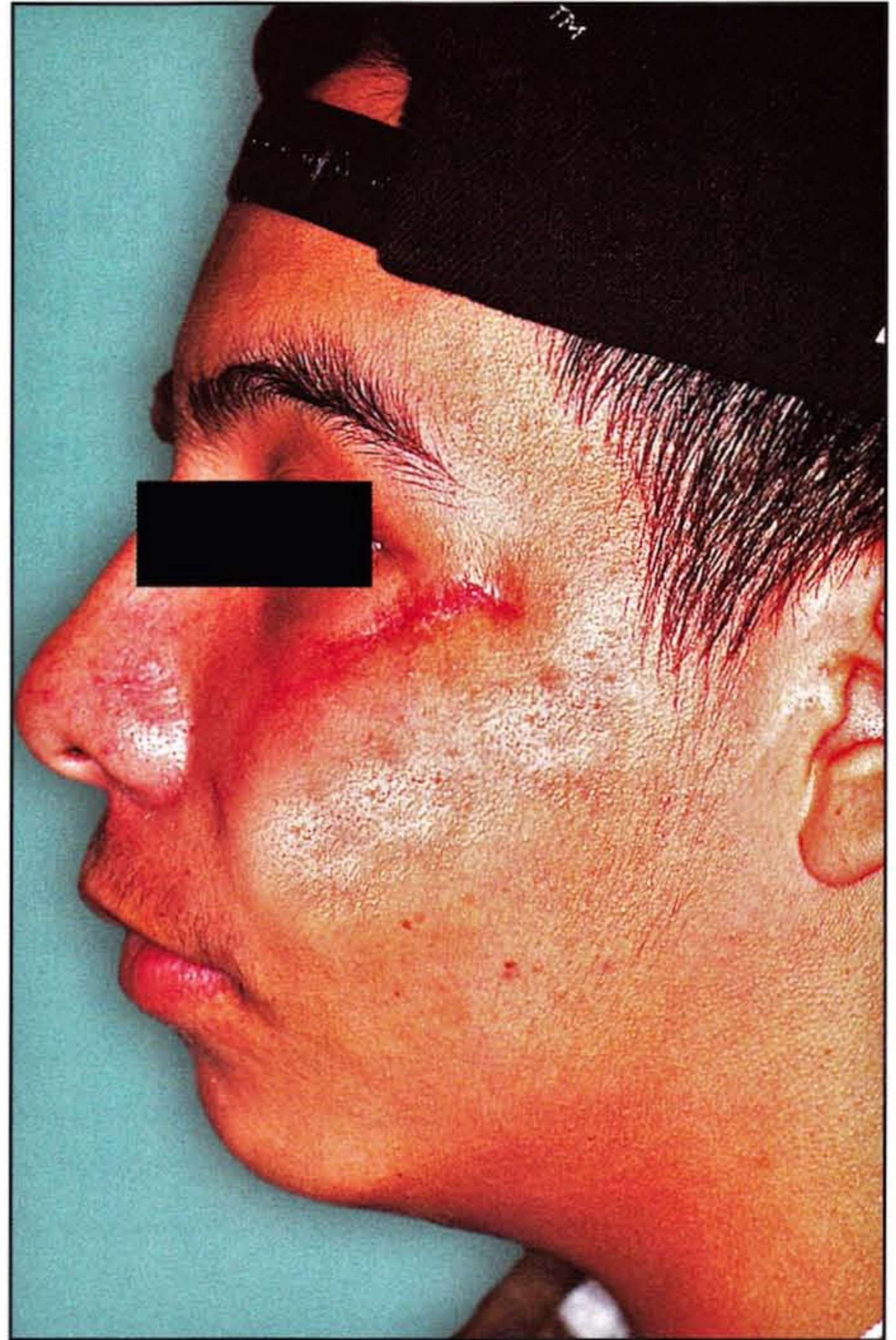

Figure 12. Postoperative lateral view. Overcorrection does not appear to be necessary with the use of this technique.

hydroxyapatite use in various areas of the head and neck.¹⁰⁻¹² The ability of the complex to act as a scaffold for bone ingrowth was confirmed by the histologic demonstration of bone ingrowth into it. Interestingly, even biopsies from the center of the complex, an area well away from bone contact, demonstrated bone ingrowth. The mild fibrous reaction noted in response to the complex may, it is postulated, give rise to a localized increase in fibroblast growth factors that have been shown to increase bone ingrowth into porous hydroxyapatite in an animal model.¹³ This has not been conclusively demonstrated in humans. The possibility of hydroxyapatite acting as a carrier for bone morphogenetic protein has been investigated, and would be a potentially useful adjunct to the reconstructive method outlined in this article.¹⁴

SUMMARY

It is the unusual patient with severe comminution of the maxillofacial skeleton who would benefit from the use of a titanium mesh-hydroxyapatite complex. Although initially promising, the outlined method needs to be prospectively evaluated in large numbers of patients before it can be put forth as a standard technique in the armamentarium of maxillofacial trauma surgeons.

REFERENCES

1. Haug RH, Savage JD, Likavec MJ, Conforti PJ. A review of 100 closed head injuries associated with facial fractures. *J Oral Maxillofac Surg* 1992;50(3):218-222.
2. Haug RH, Prather J, Indresano AT. An epidemiologic survey of facial fractures and concomitant injuries. *J Oral Maxillofac Surg* 1990;48(9):926-932.
3. Shumrick DA. Maxillofacial Trauma. Malar Zygomatic Fractures in Maxillofacial Trauma. Baltimore, MD:Williams and Wilkins;1984:340.
4. Boyne JP, Fremming BD, Walsh R, Jarcho M. Evaluation of ceramic hydroxyapatite in femoral defects. *J Dent Res* 1978;57A:108.
5. Friedman CD, Costantino PD, Jones K, et al. Hydroxyapatite cement. II. Obliteration and reconstruction of the cat frontal sinus. *Arch Otolaryngol Head Neck Surg* 1991; 117(4):385-389.
6. Costantino PD, Friedman CD, Jones K, et al. Experimental hydroxyapatite cement cranioplasty. *Plast Reconstr Surg* 1992;90(2):174-191.
7. Kveton JF, Friedman CD, Costantino PD. Indications for hydroxyapatite cement reconstruction in lateral skull base surgery. *Am J Otol* 1995;16(4):465-469.
8. Yung MW. The use of hydroxyapatite granules in mastoid obliteration. *Clin Otolaryngol* 1996;21(6):480-484.
9. Fukase Y, Takagi S, Eanes ED. Setting reactions and compressive strength of calcium phosphate cement. *J Dent Res* 1989;68:398.
10. Glasgow BJ, Weinberg DA, Shorr N, Goldberg RA. Draining cutaneous fistula associated with infection of hydroxyapatite orbital implant. *Ophthal Plast Reconstr Surg* 1996;12(2):131-135.
11. Piattelli A, Cosci F, Scarano A, Trisi P. Localized chronic suppurative bone infection as a sequela of peri-implantitis in a hydroxyapatite-coated dental implant. *Biomaterials* 1995;16(12):917-920.
12. Weissman JL, Snyderman CH, Hirsch BE. Hydroxyapatite cement to repair skull base defects: Radiologic appearance. *AJNR Am J Neuroradiol* 1996;17(8):1569-1574.
13. Wang JS, Aspenberg P. Basic fibroblast growth factor promotes ingrowth in porous hydroxyapatite. *Clin Orthop* 1996;333:252-260.
14. Ono I, Gunji H, Kaneko F, et al. Efficacy of hydroxyapatite ceramic as a carrier for recombinant human bone morphogenetic protein. *J Craniofac Surg* 1995;6(3):238-244.