

Rethinking Nasal Osteotomies: An Anatomic Approach

C. Spencer Cochran, MD; Yadranko Ducic, MD, FRCS(C), FACS; Robert J. DeFatta, MD, PhD

Objectives: To review our experience with our anatomic (medial, transverse, and lateral) nasal osteotomy technique for correcting the asymmetric bony nasal vault in esthetic and functional rhinoplasty. **Methods:** All patients undergoing anatomic nasal osteotomy technique by the senior author (Y.D.) from August 1997 to August 2005 with a minimum follow-up of 6 months were reviewed. Preoperative and postoperative photographs and clinical examination were analyzed to determine restoration of a symmetric bony nasal vault configuration. **Results:** A total of 322 patients met the inclusion criteria. Percent of patients who had favorable results with restoration of a symmetric bony nasal vault configuration was 98.1%. Six (1.9%) patients required revision surgery at the level of the nasal bones with repeat osteotomies or dorsal rasping. All six of these patients had favorable outcomes after revision surgery. **Conclusions:** The anatomic nasal osteotomy technique represents an effective, simple, and logical approach for correcting asymmetric bony nasal vault.

Laryngoscope, 117:662–667, 2007

INTRODUCTION

The bony nasal vault is comprised of the paired nasal bones centrally and the nasal processes of the maxillae laterally (Fig. 1).¹ Together, these structures create an anatomic arch, with the septum attaching to the undersurface of the nasal bones in the midline.² Esthetically, the lateral aspects of the nasal bones define the dorsal nasal width and contribute to the dorsal esthetic lines along the upper one third to one half of the nose. The distance between the nasal process of each maxilla defines the width of the bony nasal base, which should approximate 80% of the alar width. Abnormalities of bony nasal vault morphology (i.e., malposition

of the nasal bones or nasal processes of the maxillae) can manifest as bony nasal vault asymmetry, a widened dorsum, or a combination of the two (Fig. 2).

Nasal osteotomies are frequently performed as part of both functional and esthetic rhinoplasties to correct these bony deformities. Although there continues to be considerable debate among rhinoplasty surgeons as to the optimal technique, there is less debate over the indications for performing nasal osteotomies. These include 1) narrowing a widened dorsum, 2) closing an open-roof deformity after dorsal hump reduction, 3) and correcting nasal deviation of the bony nasal vault that is esthetically or functionally relevant.³

Numerous descriptive terms have been applied to describe the pattern of nasal osteotomies including low-to-high, high-to-high, high-low-high, etc. (Fig. 3). These terms are meant to describe the path of the osteotomies along the nasal sidewall. Traditional methods of performing osteotomies rely on making low, symmetric lateral bony cuts along the nasal process of each maxilla, regardless of whether they are performed percutaneously (perforated) or transnasally (continuous).⁴ Medial oblique osteotomies or in-fracturing are required to manipulate the osteotomized lateral bony nasal vault segments. Although effective at narrowing a wide bony base, these techniques often do not adequately correct asymmetry of the bony nasal vault when the deviation occurs either centrally or higher along the nasal sidewall because of malposition of the nasal bones. This is because the septum and the medial portions of the nasal bones between the medial oblique osteotomies (or lines of in-fracturing) are generally not manipulated (Fig. 4). Thus, restoring a symmetric bony nasal vault configuration in these instances requires a modification of current techniques.

The goal of our anatomic (incorporating medial, transverse, and lateral) nasal osteotomy approach is to produce a symmetric nasal bone configuration and to re-establish the natural arch of the bony nasal vault. We present a logical, anatomic approach to performing percutaneous osteotomies to correct an asymmetric bony nasal vault.

Technique

In the majority of cases, the nasal osteotomies are performed before any septal work because nasal bone manipulation may realign a deviated septum into a more favorable

From the Department of Otolaryngology–Head and Neck Surgery (C.S.C., Y.D., R.J.D.), The University of Texas Southwestern Medical Center at Dallas, Dallas, Texas, U.S.A., the Gunter Center for Aesthetics and Cosmetic Surgery (C.S.C.), Dallas, Texas, U.S.A.; and the Division of Otolaryngology and Facial Plastic Surgery (Y.D.), John Peter Smith Hospital, Fort Worth, Texas, U.S.A.

Editor's Note: This Manuscript was accepted for publication December 6, 2006.

Send correspondence to Dr. Y. Ducic, Vice Chairman, Department of Surgery, JPS Health Network, 1500 South Main Street, Suite 303, Fort Worth, TX 76104. E-mail: yducic@sbcglobal.net

DOI: 10.1097/MLG.0b013e318030e3ff

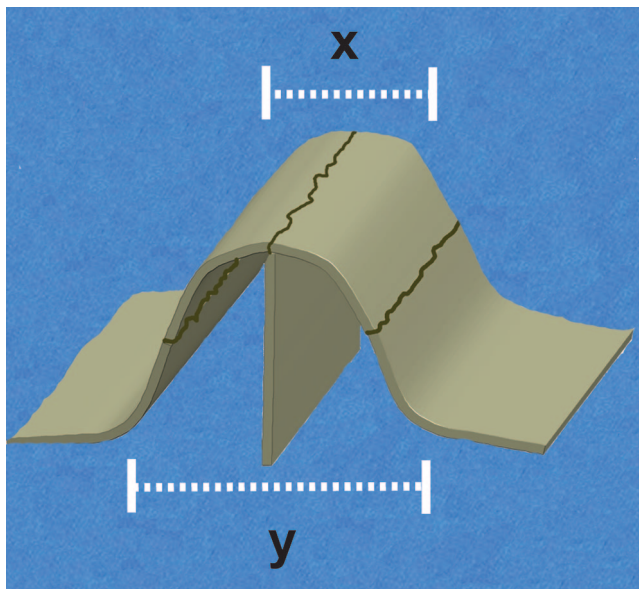


Fig. 1. Normal bony nasal vault comprised of paired nasal bones centrally and nasal process of each maxilla laterally. Dorsal nasal width (x) and bony nasal base width (y).

location and may allow an improved appreciation of the true extent of septal deviation. First, the periphery of the nasal bones is marked on the dorsum with a marking pen, which is the planned path of the anatomic (medial, transverse, and lateral) osteotomies (Fig. 5). Next, local anesthetic (1% lidocaine with 1:100,000 epinephrine) is judiciously injected along the nasal sidewall with care not to obscure the topographic anatomy (0.5 mL per side).

Before performing the lateral and transverse osteotomies, continuous medial osteotomies are created parallel

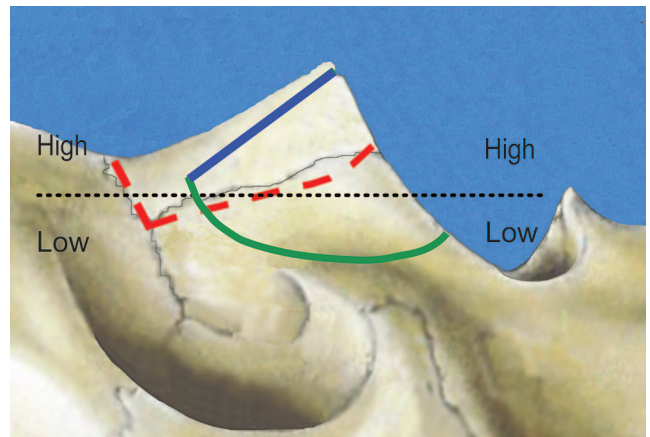


Fig. 3. Patterns of lateral osteotomies. Anatomic osteotomies (red dashed line) with high-low-high path along nasal sidewall compared with low-to-high lateral osteotomy (green solid line) with medial oblique osteotomy (blue solid line).

and immediately adjacent to the dorsal septum using a 4 mm straight, unguarded osteotome. These medial osteotomies should extend cephalad to the junction of the nasal bones with the nasal process of the frontal bone. A change in the timbre of the osteotome is often noted as the dense frontal bone is encountered.

After completing the medial osteotomies, the lateral and transverse percutaneous osteotomies are made. The side (concave) to which the surgeon wishes to move the bony vault is addressed first. A 2 mm stab incision is created at the superolateral aspect of the nasal bones within the nasofacial crease. A sharp 2 mm unguarded osteotome is introduced through the incision and is insinuated perpendicular to the bony vault at the nasomaxillary suture. A

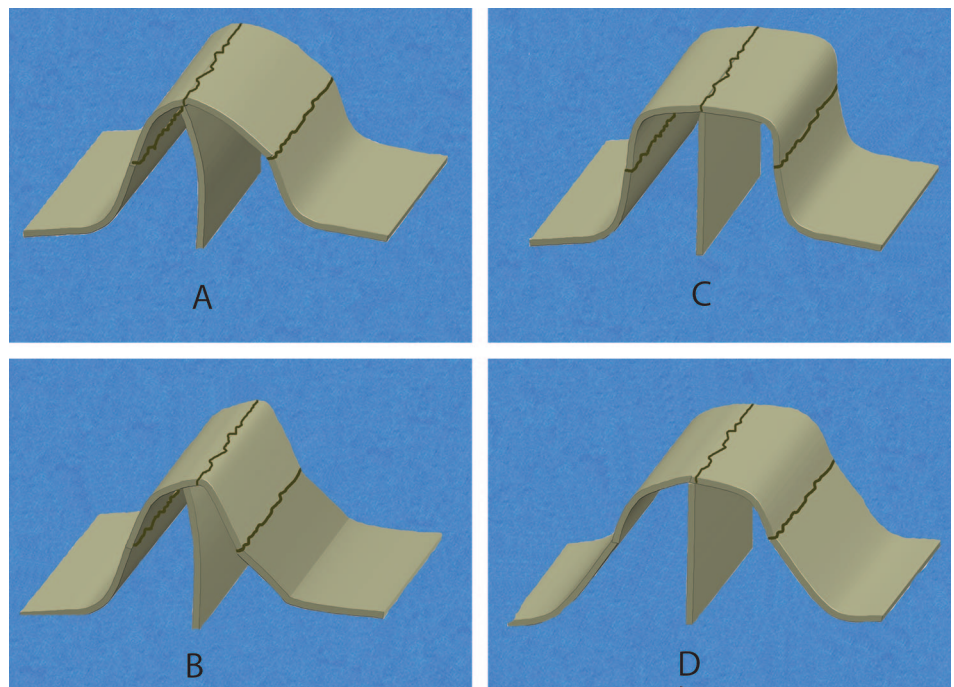


Fig. 2. Abnormalities of bony nasal vault morphology. (A) Asymmetric nasal bones. (B) Asymmetric nasal bones and asymmetric nasal process of maxilla. (C) Wide nasal bones causing excessive dorsal nasal width. (D) Wide nasal processes of maxillae causing wide bony nasal base.

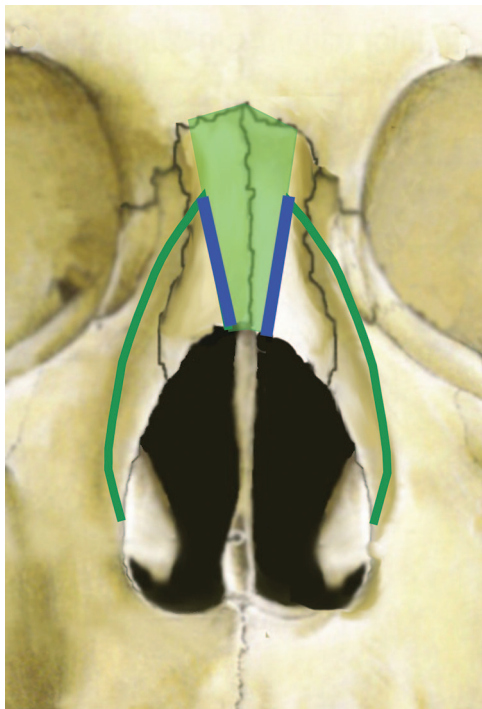


Fig. 4. Traditional low lateral osteotomy (green solid line) with medial oblique osteotomy (blue solid line). Note that central portion of bony nasal vault (green shaded area) is not addressed with this technique.

mallet is used to create the first perforated osteotomy in the lateral osteotomy sequence. The osteotome is then rotated 90 degrees within the incision site to perform the first perforation of the transverse osteotomy. The second transverse perforation is created horizontally at the cephalic edge of the nasal bone along the nasofrontal suture line. If the osteotome does not easily penetrate the bone

(indicative of the dense frontal bone rather than the nasal bone), it is relocated more caudally. Depending on nasal bone width, a third transverse perforation is made before returning to the lateral nasal sidewall to complete the lateral osteotomy.

After completion of the transverse perforated osteotomies, the 2 mm osteotome is used to palpate the initial lateral osteotomy site. The osteotome is positioned caudally along the nasomaxillary suture line, leaving a 2 to 3 mm interval of intact bone (approximated by the width of the osteotome) before performing the next lateral perforation. The osteotome is then advanced caudally, and the perforations are created in a “postage stamp” fashion until reaching the piriform aperture. The final lateral perforated osteotomy is usually created high along the piriform aperture with care taken to leave an intact triangle of bone to preserve the anterolateral attachment of the inferior turbinate. Before creation the final osteotomy, the osteotome is rotated 45 degrees toward the midline. Essentially, the goal is to follow the natural edge of the nasal bones medially, superiorly, and laterally.

Once the osteotomies are completed, a Boise elevator is introduced into the nasal cavity and placed along the under-surface of the nasal bone on the side (concave deformity) to which the surgeon wishes to move the nasal vault. The thumb of the surgeon’s other hand is used to stabilize the lateral nasal sidewall as the Boise elevator is rotated laterally to move the nasal bone into position.

The osteotomies for the contralateral (convex deformity) side are then addressed in a similar fashion. Once the osteotomies are completed, the nasal bone and septum are moved medially with controlled, firm pressure with use of the surgeon’s thumb overlying a surgical gauze. It is of the utmost importance to lateralize the side with the concave deformity first because this creates the space needed to medialize the convex deformity.

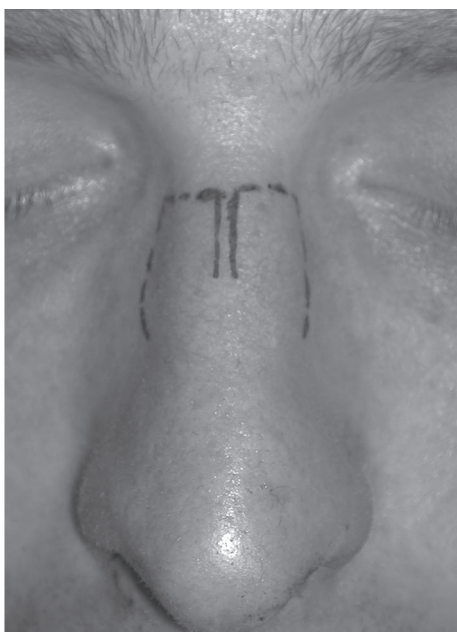
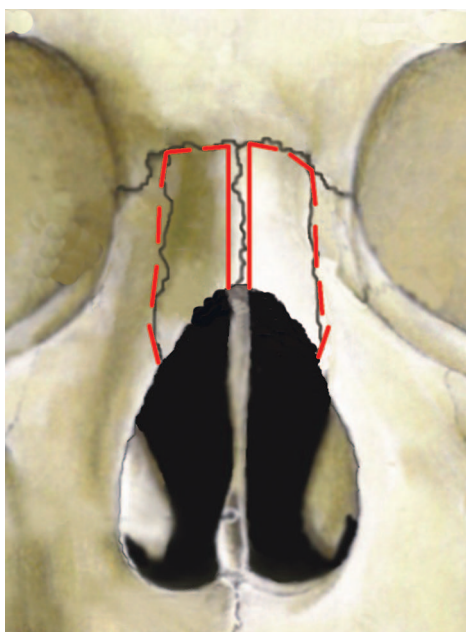


Fig. 5. Anatomic (medial, transverse, and lateral) osteotomies around periphery of nasal bones (left). Patient with planned anatomic osteotomies drawn with surgical marking pen (right).

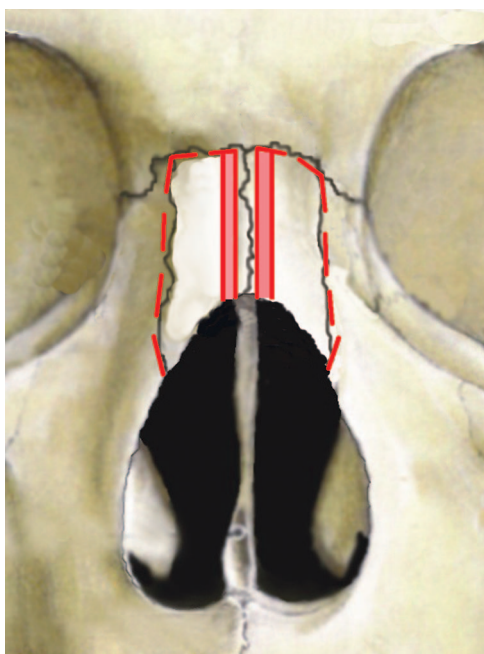


Fig. 6. Variation of anatomic osteotomy technique to narrow excessively wide nasal bones: Paramedian osteotomies are made 2 mm lateral to midline, and medial osteotomies are performed to remove intervening thin strip of bone (shaded area) between dorsal septum and paramedian osteotomies. Transverse and lateral anatomic osteotomies are then completed to close resulting open roof deformity.

This technique can be modified to effectively address excessive bony nasal vault width. If excessive dorsal width is caused solely by wide nasal bones, medial and paramedian medial osteotomies are performed. On average, 4 mm of width is removed in patients requiring such a procedure. This distance is split between the two sides of the dorsum. Initially, a straight osteotome is used to create a paramedian osteotomy 2 mm lateral to the midline (Fig. 6). Next, a medial osteotomy is performed in its usual location, hugging the dorsal septum, and in the process removing the intervening thin osseous bridge between the dorsal septum and the paramedian osteotomy. Transverse and lateral anatomic osteotomies are then performed to close the resulting dorsal gap.

If, however, the nasal dorsum is wide as a result of a widened bony nasal base (i.e., nasal process of the maxilla), the lateral sequence of the anatomic osteotomies must be modified to prevent a “step-deformity,” which can occur if the lateral osteotomies are created too high along

the nasal side wall (Fig. 7). If the surgeon wishes to narrow the bony base, a “step-deformity” can be avoided by creating the lateral osteotomies further down along the nasal sidewall where the bony nasal vault transitions into the maxilla. If the surgeon simply wishes to correct the deviation without attempting to narrow the bony base, then anatomic lateral osteotomies are created in their usual location, and the nasal bones are repositioned with avoidance of medial displacement.

Rarely, a double-level lateral osteotomy may be required for severe nasal deformities. The lower osteotomy can be made either by way of a percutaneous or intranasal approach and should be made only after the higher osteotomy is completed because a stable bony segment is needed to complete the anatomic osteotomy higher along the nasal sidewall.

At the conclusion of the procedure, the nasal dorsum is taped from the radix to the supratip, and an external dorsal splint is placed over the bony vault to rigidly bolster the repositioned nasal bones as healing progresses. In the event that one or both of the osteotomized bony segments is unstable, an intranasal bolster of methylcellulose may be placed under the collapsed nasal bone to temporary hold it in position.⁵ During the postoperative period, patients are instructed to avoid contact sports or wearing eyeglasses for the first 6 weeks after surgery to prevent shifting of the osteotomized bony segments.

RESULTS

We conducted a retrospective review of all patients undergoing rhinoplasty, both esthetic and functional, who required nasal osteotomies to realign deviated or asymmetric nasal bones performed by the senior author (Y.D.) between August 1997 and August 2005. A total of 322 patients underwent the anatomic nasal osteotomy technique with a minimum follow-up of 6 months. Two hundred five females and 117 males were included in the study, with an average age of 32.4 (range, 14–85) years. Postoperative results were judged to be favorable (nasal bones returned to the midline location with restoration of a symmetric bony vault configuration) by examination of preoperative and postoperative photographs in 98.1% of patients (Fig. 8). Six (1.9%) patients required revision surgery at the level of the nasal bones with additional osteotomies or dorsal rasping to correct residual deformities. All six of these patients had favorable outcomes after revision surgery.

DISCUSSION

The external approach to perforated lateral osteotomies was popularized by Straatsma⁶ in 1961. Since that

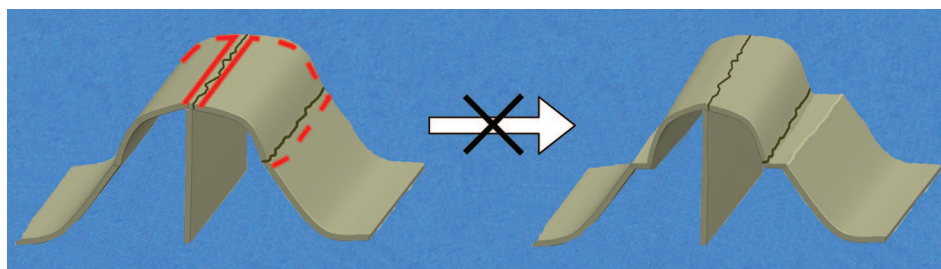


Fig. 7. Step-deformity will result if wide bony nasal base is narrowed with anatomic osteotomies too high along nasal sidewall.

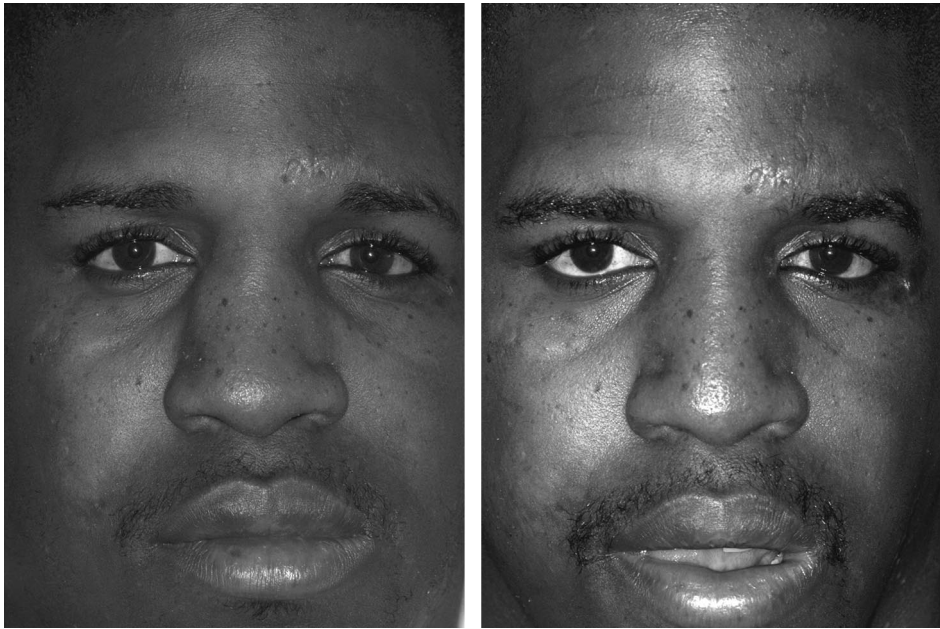


Fig. 8. Preoperative (left) versus postoperative (right) photographs of patient with asymmetric bony nasal vault and dorsal deviation corrected with anatomic osteotomy technique.

time, numerous authors have advocated the percutaneous method of lateral osteotomies as an effective method of realigning and narrowing the bony nasal vault.

Advantages of the external approach include preservation of periosteal attachments of the osseous framework that stabilize the osteotomized nasal bones, reduced lateral wall collapse, and lessened airway compromise.⁷ Perforating osteotomies also cause less intranasal injury and less soft-tissue disruption, thus minimizing bleeding and

subsequent ecchymosis and edema.⁸ This point was reinforced when Rohrich et al.⁹ found a statistically significant reduction in intranasal mucosal injury from external percutaneous osteotomies as compared with internal continuous osteotomies in fresh cadavers.

One of the criticisms of the percutaneous technique centers on the fact that an incision, albeit small, is made on the exterior of the nose and may cause scarring. Gryskiewicz¹⁰ has shown that the resulting scar is

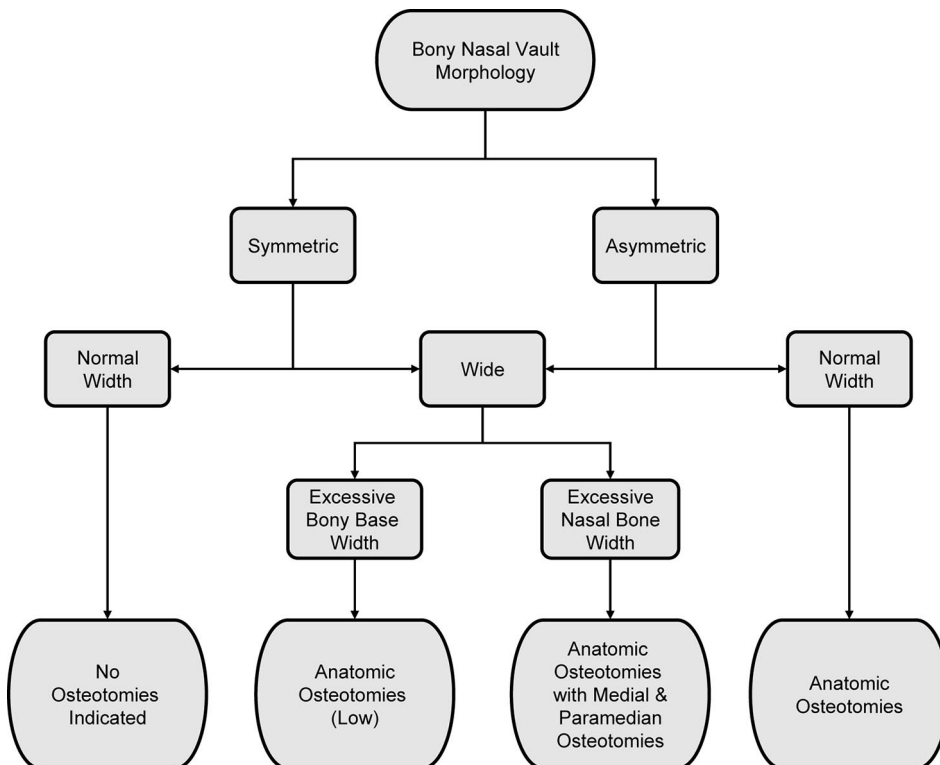


Fig. 9. Anatomic nasal osteotomy algorithm.

imperceptible in the vast majority of cases. In our experience, this has not proved to be a problem either. Inadequate results, although possible because of improper technique, are often the result of nasal bone shifting caused by early repeat trauma, the use of eyeglasses, or patients manipulating the external dorsal splint during the early postoperative period.

Traditional osteotomy techniques (both percutaneous and intranasal) use bony cuts or perforations lateral to the nasal bones along the nasal process of the maxilla. Our approach to perforated percutaneous osteotomies is different in that the nasal bones themselves are osteotomized anatomically at or near their respective suture lines. The main advantage of the anatomic nasal osteotomy technique is that each nasal bone can be manipulated independently, including the central portion, to optimize functional and esthetic results. It produces a very stable and controlled result that allows for correction of even minor bony nasal vault asymmetry while maintaining nasal airway patency.

Although the general pattern of anatomic osteotomies can be considered a “high-low-high” configuration, the actual path is dictated by the bony nasal vault morphology. The technique can be modified to address excessive bony base width by simply creating the lateral osteotomy lower on the nasal process of the maxilla to narrow the base and prevent a “step deformity.” Rarely, complex bony base abnormalities that include both a wide nasal process of the maxilla and an asymmetric nasal bone configuration may require a double-level lateral osteotomy in addition to the anatomic osteotomies.¹¹

Thus, the anatomic approach is a versatile technique that produces stable, consistent, and controlled results in a variety of clinical scenarios (Fig. 9). It allows for correction of even minor (e.g., 2–3 mm) deviations while maintaining bony vault stability and airway patency. We encountered no significant difficulties using this technique.

CONCLUSIONS

The individual surgeon’s choice of technique for nasal osteotomies is often based on experience. However, achiev-

ing reliable, consistent, and esthetically pleasing results remain a technical challenge with current techniques. The main advantage of the anatomic nasal osteotomy technique is that it produces a very stable and controlled result that allows for correction of even minor bony nasal vault asymmetry while maintaining nasal airway patency. Because the nasal bones themselves are osteotomized anatomically at or near their respective suture lines, each nasal bone can be manipulated independently, including the central portion, to optimize functional and esthetic results. This technique is simple, effective, and easy to teach and perform. It leads to favorable results in over 98% of patients.

BIBLIOGRAPHY

1. Gray H. *Anatomy, Descriptive and Surgical*. Philadelphia: Running Press, 1974.
2. Most SP, Murakami CS. Nasal osteotomies: anatomy, planning, and technique. *Facial Plast Surg Clin North Am* 2002;10:279–285.
3. Gruber RP. Aesthetic and technical aspects of nasal osteotomies. *Oper Tech Plast Reconstr Surg* 1995;2:2–15.
4. Gryskiewicz JM, Gryskiewicz KM. Nasal osteotomies: a clinical comparison of the perforating methods versus the continuous technique. *Plast Reconstr Surg* 2004;113:1445–1458.
5. Ducic Y, Hilger PA. A reliable absorbable intranasal bolster for proper maintenance of fractured nasal bone position. *Rhinology* 1999;37:88–89.
6. Straatsma CR. Surgery of the bony nose: Comparative evaluation of the chisel and saw technique. *Plast Reconstr Surg* 1961;28:246.
7. Tardy ME, Denney JC. Micro-osteotomies in rhinoplasty. *Facial Plast Surg* 1984;1:137–145.
8. Byrne PJ, Walsh WE, Hilger PA. The use of “inside-out” lateral osteotomies to improve outcome in rhinoplasty. *Arch Facial Plast Surg* 2003;5:251–255.
9. Rohrich RJ, Minoli JJ, Adams WP, Hollier LH. The lateral nasal osteotomy in rhinoplasty: an anatomic endoscopic comparison of the external versus the internal approach. *Plast Reconstr Surg* 1997;99:1309.
10. Gryskiewicz JM. Visible scars from percutaneous osteotomies. *Plast Reconstr Surg* 2005;116:1771–1775.
11. Westreich RW, Lawson W. Perforating double lateral osteotomy. *Arch Facial Plast Surg* 2005;7:257–260.