

The Double Transposition Flap for Closure of the Extremely Wide Hard Palate Cleft

Sivi Bakthavachalam, MD; Yadranko Ducic, MD, FRCSC

Repair of the extremely wide hard palate cleft can be done effectively with a double transposition flap. All cases referred for closure of cleft palates from 1997 to 2005 were considered for this study. Of these, 6 were classified as extremely wide cleft palates thought not to be treatable with standard closure techniques. A double transposition flap was used in each case. All patients tolerated the procedure well; no flap failure or dehiscence was noted; and none has required secondary repair. All patients tolerated an appropriate diet following flap repair. Two patients who were gastrostomy tube dependent preoperatively no longer required gastrostomy tubes postoperatively.

Arch Facial Plast Surg. 2006;8:123-127

Isolated cleft palate has been reported to occur in 1 in 2000 live births.¹ French dentist Lemonnier was the first to successfully repair a congenital cleft palate in the 1760s using a 3-stage operation.¹ A number of techniques for closure of the cleft palate deformity have evolved since that time. Variations exist in flap design, but also applications of any technique will vary according to cleft dimension, location, bilaterality, or unilaterality.

Schweckendiek originally described a 2-stage palatoplasty used for closure of the soft and hard palate in 2 separate procedures to allow time for adequate maxillofacial growth.¹ The Furlow double opposing z-plasty was designed to improve speech results without compromising midfacial development and also lengthens the soft palate without using tissue from the hard palate.² The von Langenbeck palatoplasty³ closes incomplete cleft palates without lengthening the palate by advancing bipediced mucoperiosteal flaps medially. The Veau-Wardill-Kilner pushback palatoplasty is also applicable for closure of incomplete clefts and provides an increased palatal length at the expense of leaving denuded bone.¹ The Bar-

dach⁴ 2-flap palatoplasty can be used for complete clefts of the palate and alveolus.¹ All techniques would ideally achieve optimal speech development without significant velopharyngeal insufficiency and avoid abnormal maxillofacial growth with single-stage closure.

While many of these techniques can be used for closure of most cleft palatal defects, they cannot be easily applied for repair of the extremely wide cleft palate. Attempts at closure of such clefts with these techniques may place the palatal tissue under great tension and result in a higher incidence of postoperative fistula formation. An *extremely wide cleft palate* has been defined as a palatal defect greater than 60% of the width of the entire palate or in which the width of both palatal shelves is less than the width of the palatal defect.⁵ These massive palatal defects may be congenital, as seen in Pierre Robin syndrome, or may be the result of excision of palatal tumors in older individuals. A variety of surgical methods have been described to repair wide cleft palatal defects, including an elongated pharyngeal flap with palatoplasty,⁶ free tissue transfer flaps,⁷⁻¹² buccal musculomucosal flaps,^{13,14} and a mucoperiosteal hinge flap with pushback palatoplasty.¹⁵ Despite the multitude of these advanced techniques for the repair of an extremely wide cleft pal-

Author Affiliations: Department of Otolaryngology–Head and Neck Surgery, University of Texas Southwestern Medical Center, Dallas, and the Division of Otolaryngology and Facial Plastic Surgery, John Peter Smith Hospital, Fort Worth, Tex.

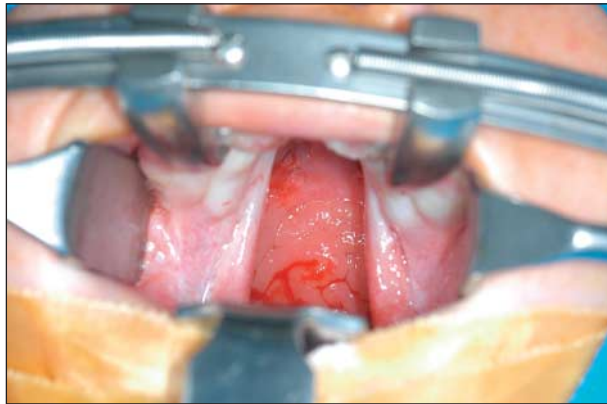

Figure 1. Preoperative photograph of a wide cleft palate prior to flap elevation.

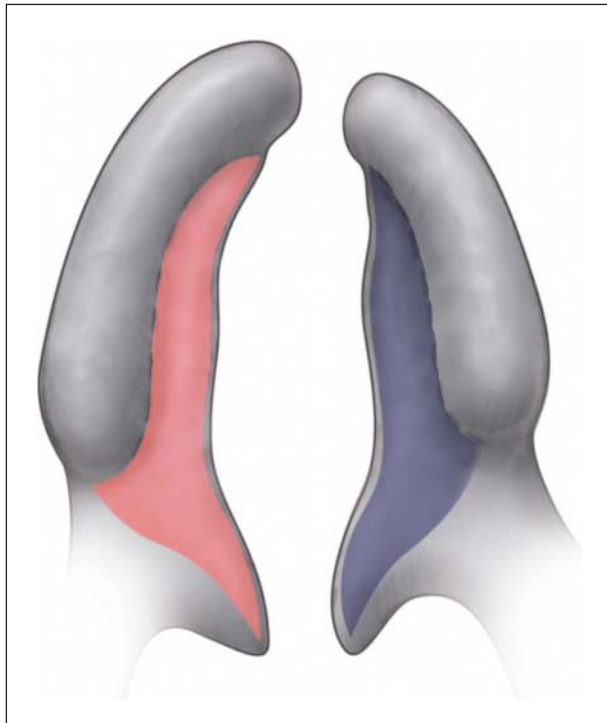


Figure 2. Faint dashed lines mark the mucoperiosteal incisions on the oral side of the cleft palate prior to elevation of the palatal flaps.

ate, they are all challenging to perform with consistently good results.

Herein, we review our favorable experience in the closure of the extremely wide cleft palate by introducing a novel technique called the double transposition flap. This method is surgically less complicated than current techniques and produces rewarding results.

METHODS

All cleft palate closures performed by the senior author (Y.D.) from 1997 to 2005 were reviewed. The patients classified as having an extremely wide cleft palate, where the width of the palatal defect was greater than 60% of the width of the entire palate or where the width of both palatal shelves was less than the width of palatal defect, were included in this review (**Figure 1**).

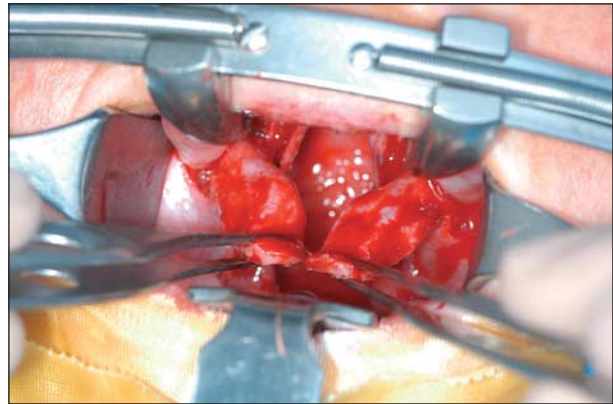


Figure 3. Intraoperative photograph illustrating elevation of the flaps on the hard palate.

TECHNIQUE

The senior author prefers to perform cleft palate repairs when the child has reached age 12 to 18 months. Earlier repair is undertaken in children who exhibit prolonged failure to thrive attributed to the cleft palate despite intensive conservative nonsurgical intervention with speech therapy.

Following induction of general anesthesia, a Dingman mouth gag is inserted allowing excellent visualization of the cleft palate. For vasoconstriction, 0.5% xylocaine with 1:200 000 epinephrine solution is infiltrated into the palatal mucosa bilaterally. After enough time has elapsed to allow for adequate vasoconstriction, the flaps are delineated. Bilateral transposition flaps are marked, incised with a No. 15 blade, and elevated in a subperiosteal tissue plane (**Figure 2** and **Figure 3**). They are pedicled on the greater palatine vessels, which are freed as much as possible by releasing and occasionally incising the periosteal sleeve around the vessels.

The soft palate musculature is then released from its attachment to the posterior margin of the hard palate. The flaps are transposed in a transverse fashion, allowing for tension-free closure (**Figure 4** and **Figure 5**). The incision lines run transversely across the hard palate rather than longitudinally, as is usually the case. Closure is achieved in 2 layers (nasal and oral) with 4.0 Vicryl sutures (Ethicon Inc, Piscataway, NJ) in an interrupted fashion (**Figure 6** and **Figure 7**). The mouth gag is released every 20 minutes to help prevent tongue edema. The patient resumes oral feeding the day after surgery.

RESULTS

A total of 6 patients underwent double transposition flap closure of extremely wide cleft palates. Average age of closure was 13.5 months (age range, 8-18 months). Each cleft width was at least 60% of the width of the entire hard palate (range, 60%-75%). All repairs were successful with no evidence of fistula or wound breakdown. Two patients were gastrostomy dependent preoperatively and were tolerating an age-appropriate diet postoperatively. None of this series of patients has required pharyngeal flap or other treatment for velopharyngeal insufficiency.

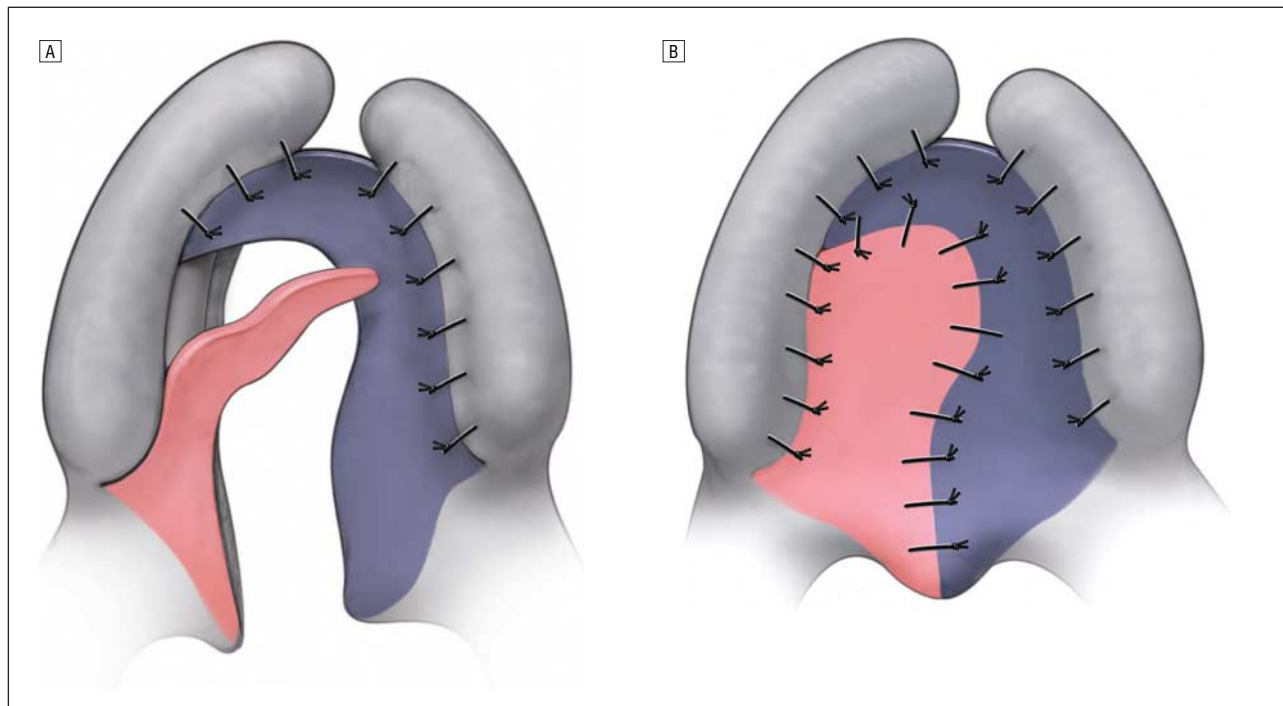


Figure 4. Flap closure. A, Flaps on the hard palate are elevated, transposed, and inset medially. B, Final flap inset with transverse closure at hard palate with longitudinal closure on soft palate.

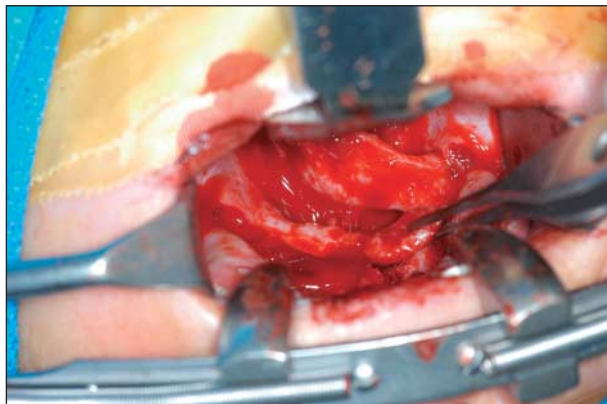


Figure 5. Intraoperative photograph illustrating the inset of the double transposition flaps.

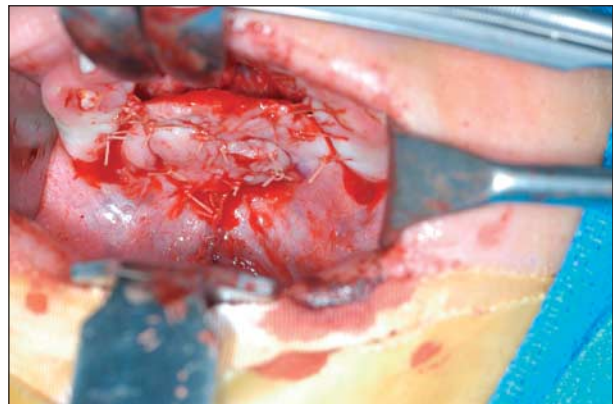

Figure 6. Intraoperative photograph after sutured closure of the palatal flaps.

COMMENT

While wide palatal defects may be clinically identifiable by many surgeons, objective definitions of a wide palatal cleft are scarce in the current literature. Bardach⁴ defines a wide cleft palate as one in which the distance between the medial edges of the hard palate is more than 1.5 cm.⁴ The “massive” palatal defect has been reported as a defect where the width of the defect is larger than the width of both palatal shelves combined or where the width of the bony palatal defect is greater than 60% of the width of the entire palate.⁵ Surgical closure of both wide and extremely wide cleft palates proves to be a formidable task for the cleft palate surgeon. Standard methods for cleft palate repair are often not physically capable of closing extremely wide defects and can lead to

a higher postoperative oronasal fistula rate as a result of excessive tension placed on the palatal tissue. As a result, a variety of techniques have been specifically developed and are described in the literature for closure of extremely wide cleft palates.

Free tissue transfers are commonly reported in the literature to close extremely wide palatal defects by providing well-vascularized tissue to the area with minimal scarring.¹⁶ Free flaps can correct large defects with minimal dissection of the palate. The radial forearm free flap is well described in the literature for both primary and secondary cleft palate repair. Hallock¹⁰ described his successful experience with this flap for primary palatal repair in an adult. The radial forearm flap can be prefabricated by elevating the flap at a subfascial level and sewing a full-thickness skin graft to its undersurface. Weeks later, once the skin graft has taken, the full flap is transferred

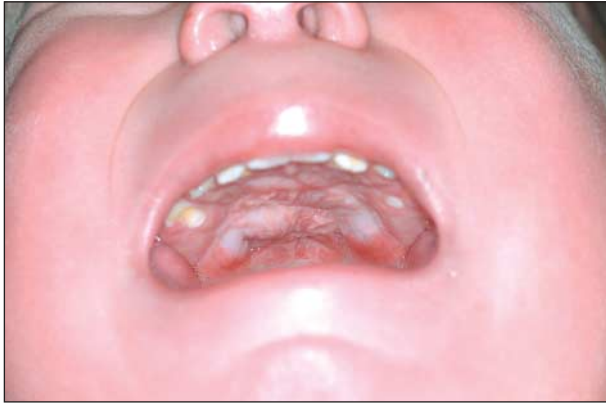

Figure 7. Postoperative photograph showing successful closure of extremely wide cleft palate.

to the palate with the provision of nasal and oral coverage. While the procedure can be done in 1 stage, prefabrication of the skin graft prior to flap transfer may avoid late flap scarring and avoids difficulty in mobilizing intraoral skin grafts at time of transfer. Chen et al¹⁶ report a series of 4 patients with oronasal fistulas who underwent secondary palatal repair with a radial forearm free flap. One of the 4 required an additional pharyngeal advancement flap for full closure. Eufinger and Machtens⁹ describe 2 cases of radial forearm flap transfer with use of iliac crest bone segments for hard palatal defects.

A brachial flap for wide cleft palate repair is described in the literature as a 3-stage surgical procedure with no complications 4 years postoperatively.¹¹ Three cases of a dorsalis pedis free flap are reported by Correa Chem and Franciosi.⁷ One patient developed an anterior hard palate fistula postoperatively. Schwabegger et al¹² treated recurrent palatal fistulas in 3 patients with a dorsalis pedis flap and successfully used an angular scapular flap based on the thoracodorsal vessels on 3 other patients. Of all the free tissue transfer techniques, the radial forearm free flap is likely the most popular because it provides a thin, long, hairless, pliable flap with large-caliber vessels that usually obviate the need for any interposition vein grafts.

Furnas⁸ reported the use of a temporal osteocutaneous island flap for wide cleft palate repair. This flap is based on the superficial temporal vessels and can be performed with a 2-staged osseous flap using parietal bone or a 1-stage osteogenic pericranial pocket flap.

As reported by Bardach,⁴ an elongated pharyngeal flap for extremely wide cleft palate closure was first described by Bengt Johanson and subsequently used by Bumsted³ on 4 patients. This technique involves raising a 3-cm-wide flap from the posterior wall of the pharynx at the level of the cricoid cartilage and extending it cranially to cover the palate for a total length of 10 cm on the nasal side of the cleft defect. Bumsted performed a 2-layer closure by using turnover flaps of nasal mucoperiosteum based on the cleft margin to assist in closing the oral side of the defect along with raising mucoperiosteal flaps. He was successful in 75% of his repairs, with 1 postoperative fistula. Holmstrom et al⁶ performed the procedure on 11 patients with wide cleft palates who were

obturator dependent. These authors reverted to the Wardill-Kilner palatoplasty technique to cover the oral side. None of their patients required additional surgery, while 2 of the 11 developed a postoperative fistula.

Lee et al¹⁵ described a 2-layer closure of wide clefts using a triangular shaped mucoperiosteal hinge flap from the anterior hard palate and bilateral rectangular shaped mucosal flaps to close the nasal side and a pushback palatoplasty to close the oral side. The authors note that this technique can be used for wide cleft palates but not the extremely wide cleft defects where the defect is wider than the sum of the width of the 2 oral mucoperiosteal flaps.

Bilateral buccal musculomucosal flaps have also been used for wide cleft palate closure. Chen and Zhong¹³ reported their experience in 26 patients with no postoperative complications. The surgery involves a horizontal incision at the junction of the soft and hard palate to separate oral mucosa from underlying levator muscle. The muscle flaps and nasal mucosa are rotated medially and sutured. Bilateral buccal musculomucosal flaps are then designed to fill in the defect between the hard and soft palate on the oral side. This use of buccal flaps for wide clefts is well established in the literature, with another report combining this technique with the Furlow double-opposing z-plasty.¹⁴ This combination achieves lengthening of the palate from the Furlow technique and reduces tension from the closure in wide clefts by adding bilateral buccal flaps.

While all of the described surgical techniques have a certain degree of success in repair of wide cleft palates, many of them require a long operating time and can be technically very difficult. The double transposition flap introduced herein retains a degree of simplicity in technique that is based on surgical methods currently applied, specifically the 2-flap palatoplasty. This factor may make the repair attractive to many cleft palate surgeons. In addition, this technique has the advantage of being able to close cleft palates of any width. The line of closure at the level of the hard palate is transverse and not longitudinal. There is some gain in length and width when complete mobilization and flap transposition has occurred. In fact, only once such gain is appreciated can complete flap release be assured. Thus far, our patient series has performed exceptionally well. Further follow-up looking at speech development, deglutition, and facial growth will be very important in determining the long-term success of this flap. Nevertheless, from our preliminary experience, this new technique has provided successful results.

In conclusion, we introduce herein a novel technique for the closure of extremely wide cleft palates and describe our experience. The double transposition flap has proven to be efficacious in our trials. It results in minimal morbidity and is less technically demanding than current techniques used for extremely wide cleft palate closure.

Accepted for Publication: July 25, 2005.

Correspondence: Yadranko Ducic, MD, FRCSC, Division of Otolaryngology and Facial Plastic Surgery, John Peter Smith Hospital, 1500 S Main St, Suite 303, Fort Worth, TX 76104 (yducic@sbcglobal.net).

REFERENCES

1. Sadove AM, Aalst V, John C, Andrew J. Cleft palate repair: art and issues. *Clin Plast Surg.* 2004;31:231-241.
2. Furlow LT Jr. Cleft palate repair by double opposing z-plasty. *Plast Reconstr Surg.* 1986;78:724.
3. Trier WC, Dreyer TM. Primary von Langenbeck palatoplasty with levator reconstruction: rationale and technique. *Cleft Palate J.* 1984;21:254-262.
4. Bardach J. *Atlas of Craniofacial and Cleft Surgery.* Vol 2. Philadelphia, Pa: Lippincott-Raven; 1999.
5. Bumsted RM. A new method for achieving complete two-layer closure of a massive palatal cleft. *Arch Otolaryngol.* 1982;108:147-150.
6. Holmstrom H, Stenborg R, Blomqvist G. Elongated pharyngeal flap in extensive clefts of the hard and soft palate. *Cleft Palate J.* 1986;23:41-47.
7. Correa Chem R, Franciosi LF. Dorsalis pedis free flap to close extensive palate fistulae. *Microsurgery.* 1983;4:35-39.
8. Furnas DW. Temporal osteocutaneous island flaps for complete reconstruction of cleft palate defects. *Scand J Plast Reconstr Surg Hand Surg.* 1987; 21:119-128.
9. Eufinger H, Machtens E. Microsurgical tissue transfer for rehabilitation of the patient with cleft lip and palate. *Cleft Palate Craniofac J.* 2002;39:560-567.
10. Hallock GG. Repair of an untreated cleft palate in an adult using a prefabricated radial forearm flap. *Ann Plast Surg.* 1997;38:69-73.
11. Namin AH. Wide cleft palate repaired by brachial flap. *Cleft Palate Craniofac J.* 1992;29:192-193.
12. Schwabegger AH, Hubli E, Rieger M, Gassner R, Schmidt A, Ninkovic M. Role of free-tissue transfer in the treatment of recalcitrant palatal fistulae among patients with cleft palates. *Plast Reconstr Surg.* 2004;113:1131.
13. Chen GF, Zhong LP. A bilateral musculomucosal buccal flap method for cleft palate surgery. *J Oral Maxillofac Surg.* 2003;61:1399-1404.
14. Mann RJ, Fisher DM. Bilateral buccal flaps with double opposing z-plasty for wider palatal clefts. *Plast Reconstr Surg.* 1997;100:1139-1143.
15. Lee SI, Lee HS, Kun H. Reconstruction of palatal defect using mucoperiosteal hinge flap and pushback palatoplasty. *J Craniofac Surg.* 2001;12:561-563.
16. Chen HC, Ganos DL, Coessens BC, Kyutoku S, Noordhoff SM. Free forearm flap for closure of difficult oronasal fistulas in cleft palate patients. *Plast Reconstr Surg.* 1992;90:757-762.

Announcement

Online Submission and Peer Review System to Be Available in May 2006

The *Archives of Facial Plastic Surgery* editorial office will be introducing an online manuscript submission and peer review system developed by eJournal-Press that will serve the needs of authors, reviewers, and editors. The new system is scheduled to go live on May 15. See <http://www.archfacial.com> for more detailed information.